This is a digital copy of a book that was preserved for generations on library shelves before it was carefully scanned by Google as part of a project to make the world's books discoverable online.

It has survived long enough for the copyright to expire and the book to enter the public domain. A public domain book is one that was never subject to copyright or whose legal copyright term has expired. Whether a book is in the public domain may vary country to country. Public domain books are our gateways to the past, representing a wealth of history, culture and knowledge that's often difficult to discover.

Marks, notations and other marginalia present in the original volume will appear in this file - a reminder of this book's long journey from the publisher to a library and finally to you.

Usage guidelines

Google is proud to partner with libraries to digitize public domain materials and make them widely accessible. Public domain books belong to the public and we are merely their custodians. Nevertheless, this work is expensive, so in order to keep providing this resource, we have taken steps to prevent abuse by commercial parties, including placing technical restrictions on automated querying.

We also ask that you:

+ *Make non-commercial use of the files* We designed Google Book Search for use by individuals, and we request that you use these files for personal, non-commercial purposes.
+ *Refrain from automated querying* Do not send automated queries of any sort to Google's system: If you are conducting research on machine translation, optical character recognition or other areas where access to a large amount of text is helpful, please contact us. We encourage the use of public domain materials for these purposes and may be able to help.
+ *Maintain attribution* The Google "watermark" you see on each file is essential for informing people about this project and helping them find additional materials through Google Book Search. Please do not remove it.
+ *Keep it legal* Whatever your use, remember that you are responsible for ensuring that what you are doing is legal. Do not assume that just because we believe a book is in the public domain for users in the United States, that the work is also in the public domain for users in other countries. Whether a book is still in copyright varies from country to country, and we can't offer guidance on whether any specific use of any specific book is allowed. Please do not assume that a book's appearance in Google Book Search means it can be used in any manner anywhere in the world. Copyright infringement liability can be quite severe.

About Google Book Search

Google's mission is to organize the world's information and to make it universally accessible and useful. Google Book Search helps readers discover the world's books while helping authors and publishers reach new audiences. You can search through the full text of this book on the web at `http://books.google.com/`

BOSTON
MEDICAL LIBRARY
8 THE FENWAY

TRANSACTIONS

OF THE

16518

ACADEMY OF STOMATOLOGY,

JANUARY 26, 1897, TO DECEMBER 28, 1897.

REPRINTED FROM THE INTERNATIONAL DENTAL JOURNAL.

PHILADELPHIA:
PRINTED BY J. B. LIPPINCOTT COMPANY.
1898.

TON MED
NOV 13 19
LIBRARY

OGI
NOV 13 1918

OFFICERS.

1896-97.

PRESIDENT.

JAMES TRUMAN.

VICE-PRESIDENT.

EDWIN T. DARBY.

SECRETARY.

J. H. GASKILL.

TREASURER.

H. C. REGISTER.

LIBRARIAN.

WM. H. TRUEMAN.

ACADEMY OF STOMATOLOGY.

A REGULAR meeting was held by the Academy of Stomatology January 26, 1897, at its rooms 1731 Chestnut Street, the President, Dr. James Truman, presiding.

The Clinic Committee reported two clinics held the previous Saturday. One by Dr. H. E. Roberts upon novel and quickly-constructed orthodontic appliances; the other by Dr. M. H. Cryer, who exhibited a case for whom he had performed a surgical operation to facilitate the moving of a malposed cuspid tooth.

The council reported the following acknowledgment of a valuable gift of books to its library by the family of the late Professor J. E. Garretson:

The Academy of Stomatology extends to the family of the late Professor Garretson a vote of thanks for the valuable contribution of books, presented in the name of his grandson, Edmund Garretson Cooke.

The Academy of Stomatology has satisfaction in taking advantage of the opportunity to express its high appreciation of the character of Dr. Garretson and of his abundant, honorable, and advanced work in the field of oral surgery in which he was eminent.

The Academy has further pleasure in devoting the evening of January 26, 1897, to a review of the life work of Dr. Garretson.

(Signed) LOUIS JACK,
HENRY H. BURCHARD,
ROBERT HUEY,
S. H. GUILFORD,
M. H. CRYER,
Council.

The President.—The subject of the evening will be opened by an essay on "The Work of James Edmund Garretson, A.M., M.D., D.D.S.," by Dr. Burchard.

THE WORK OF JAMES EDMUND GARRETSON, A.M., M.D., D.D.S.

BY H. H. BURCHARD, M.D., D.D.S.

Modern dentistry has lost another of its architects, oral surgery its founder, and stomatology one of its greatest forces in the death of Professor Garretson.

Entering the ranks of the dental fraternity when it was hovering on the border-land of the learned professions, he saw and seized the elements of greatness residing in it, and from then to the time of his death labored incessantly to endow dentistry with the dignity which he foresaw was to be its ultimate portion.

Beginning in 1859, he brought to the practice of surgery the training and knowledge of the well-equipped dentist, and how well he blended these two aspects of practice, and what he made from them, is seen in a stupendous work on regional surgery which has remained without a rival for twenty-five years.

It is in the last edition of this great work that the present culmination of stomatology is found; and the former editions exhibit the gradual evolution of a professional condition which began in toleration and has grown to a just recognition. Examining the works upon general surgery prior to the appearance of the first edition of "Oral Surgery," it is seen that the surgical armamentarium for use in the special field embraced by Dr. Garretson was of a type strongly suggestive of the Pompeiian relics in the museum of Naples; viewing it as he left it, we find an instrument cabinet replete with devices designed to expedite and render more humane many of the major operations of surgery, and a class of mechanism fitted for use in refined operations, the authorship of which is traceable to the learned gentleman whose death two professions mourn.

The secret of much of Dr. Garretson's success was not in genius, although he was endowed with genius, but resided in work; in an indomitable energy, a keen perception, and a rigid yet luminous reasoning which was brought to bear upon the problems confronting him. Beginning, as this systematic work did, with years of patient and assiduous labor in the anatomical laboratory, no work begun was ever relinquished until the master held within his grasp a clear, full, and philosophical comprehension of every factor involved. In any work engaging his attention he was the incarnation of energy, patience, and modesty.

These were the forces brought to bear upon a field of surgery ignored or half taught by the general surgeon and beyond the province or ken of the dental fraternity as it existed before this vivifying element touched it with the wand of possibility, and at times stung it with the lash of criticism.

Before his day stomatology was in an inchoate state. There was a field common to the general surgeon and medical practitioner and to the dentist; touched by all, embraced by none; treated by all, frequently cured by none, he had lived to see the fruition of much of his toil in the development of a new field of special surgery. His innate modesty never permitted him to assume his full measure of credit due him for the part he played in this evolution.

Reviewing his published works from 1863 to 1895, there is a history beginning in a perfect familiarity of the details of anatomy, normal and morbid, and of normal and perverted physiology, which, while keeping pace year by year with the great advances in each of these fields, year by year has been generalized into guiding principles; for the teaching of principles was the key-note to his professional life.

To him no such thing as an unrelated fact existed, each in his mind stood as representative of cause or effect, and through his long and honorable career in medicine every fact, datum, or phenomenon which his experience evolved, or which came under his notice, was carefully placed in its relations with others, so that a continuous chain was formed. In his formulations there were and are matters which are seemingly not in perfect harmony with the details of the several sciences involved in medicine, yet it is readily seen that each is eminently fitted to subserve the purpose for which it was designed, to render clear to the minds of students problems which without such aid would be obscure or lead to mental confusion.

His method of teaching was purely inductive, and any means which could lead to the development of the inductive faculty in the students was applied, leaving to them the task and the acquired ability to deduce from general rules the details involved in them.

Under his touch the dry minutiæ of descriptive anatomy were clothed with alluring forms; the mind of the philosopher and poet endowing mere description with forms which chained and charmed the attention of the student. Facts and figures of biology had woven about them such a skill of interpretation that even the laity saw beauty where before was felt aversion.

Pathology and morbid anatomy were painted in such colors that

from repugnance grew an absorbing attention which surrounded even a malignant growth with an interest his listener never before dreamed of.

Surgery, problems of medicine, aye, even those of the cosmos itself, were robbed of their complexity by the magic touch of this master and brought within the comprehension of even the novice. No man more than he possessed the power, invaluable in a teacher, of seizing and fastening the attention of his hearers to whatever subject he presented. Some apparently simple and yet profound truth, presented to an audience as an aphorism, drew a ready acquiescence from all, and from that basis, step by step, the subject-matter was unfolded in an orderly sequence as forcible as it was logical.

That phase of the oratorical power which sways through the reasoning faculty rather than by the force of rhetoric amounted in him to almost a genius in itself. While none of the graces of language which stamp the polished *littérateur* were wanting in him, he scorned the mere play upon euphonism and sophistry which lend polish to and rob force from the discourses of many orators.

The induction of principles from accepted facts was his work, and how well it has been done is attested in the professional lives of thousands, and the gratitude of all who have come within the range of his influence directly or indirectly.

For a specific example of his mode of thought we may take his division of neoplasms into but two classes,—those having an explainable and those an unexplainable origin. This generalization has given rise to the opinion among some of his critics that he was wanting in appreciation of the details of pathological anatomy, and yet one of the last conversations I had with that learned philosopher was upon this subject, and he discoursed upon the origins and metamorphoses of tumors with such a profound knowledge of details as would disillusion the most carping critic.

His simplicity arose from repletion, not from lack of knowledge. This very formulation has given hundreds of pupils an insight into a matter, who, without it, might have been led into gross misconceptions, and no doubt in some cases into fatal error.

This is but one example; his thousands of former students are familiar with a multitude of others, which have served as sound and ever-present guides to them, avoiding through their application professional errors, and averting countless miseries to their patients.

One clinical teaching in particular is worthy of even more attention than it appears to have received, his method of operation for epithelioma. It was an axiom with him, that the greatest hope of cure in this malignant affection is in replacing the affected area by healthy tissue from another part, not the mere excision of the diseased structures. The records of his clinic show upon how sound a basis his opinion was formed. Not one fact amid the thousands he taught but was tabulated, classified to form part basis of some well-defined principle, and if a principle were already recognized was not placed in its proper relationship with its parent generalization.

His college chair reflected his mind; the other aspect of his teaching, his philosophical works, revealed the man himself. His philosophy was as near pure Platonism as any system could be and yet retain its distinctiveness. The Platonism of some two thousand years ago has speculation upon theoretic basis replaced by induction founded upon determined facts. Baconian lights are thrown upon Platonic pictures.

The Socratic method of exposition is applied throughout, and yet, contrary to the usual ending of a Platonic dialogue, definite answers to the problems discussed are presented.

There is not a school of philosophy from the Ionic to the Agnostic which has not been subjected to searching examination and criticism, and the results applied to an ethical code more than acceptable to Jew, Buddhist, Christian, or Mohammedan.

From the beaten track covered by all commentators he steps aside from the great mile-stones, Thales, Diogenes, Plato, Aristotle, Chrysippus, Epictetus, St. Augustine, Abelard, Averroës, Descartes, Bacon, Kant, Comte, and Spencer, to some almost forgotten thinker of the past, who has given one pearl; this Dr. Garretson has found with an unerring instinct and given it its proper position. To the contention of differing faculties, idealist and materialist, he gives his formulation,—"A thing is to the sense that uses it what to that sense it seems to be."

For his personality, it was of such a type that those who knew him best loved him most. He represented the embodiment of all the reasons which caused the later Platonists to call Christianity Platonism.

Every trait of gentleness, affection, and a belief in the brotherhood of mankind, which distinguishes the true Christian, resided in him, and found expression in acts of his life known to but himself and the beneficiaries.

The President.—Gentlemen, you have heard this able and appreciative essay on Dr. Garretson's life work. Remarks are now in order, and I will call upon Dr. Guilford to open the subject.

Dr. Guilford.—Mr. President and Fellow Members,—I had not conceived the idea of speaking upon the subject this evening, because I have already spoken and written on it. However, while listening to the paper of the evening a few remembrances recur to me, which illustrate the character of Dr. Garretson.

All who knew Dr. Garretson were impressed with certain qualities he possessed,—which were characteristics. In the first place, he was a sincere man,—absolutely, conscientiously sincere. In the second place, he was an earnest man. He never did anything in his life, I believe, but what he put his whole soul in it. No one who ever knew him doubted his sincerity. He never pretended to love a man, or to care for one, without really doing so. He never flattered any one; he often praised men, praised them to their faces, and he meant it. He was not lavish in his praise; in fact, on many occasions it was thought that he withheld praise where it was due, but when he did give it he meant it. He was so earnest that whatever he did he did with a certain degree of solemnity. He was fond of humanity. He appreciated a joke as much as any one, and yet at the same time in everything that he did there was an earnestness that impressed those about him. I suppose it was due to the fact that he was absorbed in his own contemplations. These qualities, earnestness and sincerity, commanded the respect of all who knew him.

He possessed a power to attract, not only those of his own age, but younger people, particularly young men. His influence over young men was remarkable, he influenced them because he loved them, and they felt that he was always ready to listen to anything they might confide in him. They went to him for advice and they got it; they went to him for sympathy in their troubles and he gave it to them. If they needed more material aid he was always ready to assist them. He was a remarkably charitable man,—charitable in giving material help, as well as in other ways, and yet he knew the value of money. For many years he was a demonstrator in one of our colleges; after laboring there half a day he would wash his hands and go out and eat a ten cent lunch, and yet when he came to die he had been so prudent that he had accumulated a competence.

I remember a case of destitution in a little village where I lived that was particularly pathetic in its details; one that appealed to

the sympathy of all those who knew of it, and there were very few who did. I wrote a few notes to some friends in regard to getting together a fund to assist the family. I wrote to Dr. Garretson and told him that I had requested a few of my friends to contribute five dollars apiece. He wrote back enclosing ten dollars and saying, "My dear Doctor,—Don't speak about $5.00. Let them give $10.00, and if more is needed call on me." Now, that showed the character of the man. It was this kindness of heart that attracted men to him. He not only appeared to but actually did sympathize with all who placed their confidence in him, and it was for this reason that he was beloved by so many people, particularly by the young people. I do not know that he had a single enemy. I never heard of one. I never heard a harsh or an unkind word said of him after his death; nothing but praise from every one, not so much because they appreciated his greatness in his own particular line, but because they appreciated his greatness of heart, one of his chief characteristics.

The President next called upon Dr. Cryer.

Dr. Cryer.—For eighteen years I followed that gentleman day after day and loved him as I loved no other man except my father and brother, and whenever I think of him and hear him mentioned it overcomes me and I cannot speak upon this subject.

The President called upon several gentlemen, who did not respond.

Dr. James Truman.—I should like to express briefly my feelings in regard to Dr. Garretson. I do not think the Society should pass this subject without more remarks upon a man who has done so much to elevate dentistry. We not only appreciate this part of his life work, but also that performed for surgery. He opened new lines of thought and spread abroad new ways of doing or performing surgical operations, which I think must have a lasting effect upon the medical and surgical practice. I do not know that they recognize it, but to my mind his contributions are a great force.

Dr. Garretson and myself were personal friends. We never met but it was a pleasant reunion. I enjoyed the conversation we had together on many subjects, philosophical and otherwise. I do not think as a man he was understood. I fear that when he came before the public as a speaker, his remarks were not fully comprehended. He talked generally in a language above that used by the common people, but when his thought could be absorbed and followed to legitimate conclusion, it exhibited a vital force not usual in public efforts.

I shall never forget, so long as life lasts, his address on the oc-

casion of the Well's Memorial Meeting. It struck me as being one of the most forcible, as well as one of the most powerful, addresses that I had ever listened to, and yet I fear the majority of that audience did not fully appreciate it. There is something in becoming acquainted with a man's mode of speech in order to comprehend an address of this character. I sat under Dr. Garretson in his philosophical lectures during one entire course, therefore I became more familiar with his mode of thought, and probably better able on that account to reap the value of his ideas. He, to my mind, was one of the great men in dentistry, and we are here to-night not so much to mourn his loss as to remember him in his work.

INCIDENTS OF PRACTICE.

Dr. Jack.—I wish to present the report from the notes of the conservative treatment of a pulp which I believe to be the first attempt of the kind made by me. The date was in September of 1866. The surface of decay the occlusal. The condition one of evident exposure to the carious denture, the last layers of which were not removed. A concave cap made of a heavy mat of gold foil was filled with a paste composed of hypophosphite of lime and glycerin; this, being laid over the part, was next covered with a layer of gutta-percha. The cavity was then filled with amalgam.

On January 25, 1872, this case was opened. On removing the fillings and a thin layer of decayed dentine a distinct pulp opening was found which was unmistakable. The size of it was about the twentieth of an inch and was of circular form. On the examination of this aperture a solid obstruction was found at a short distance. This was sensitive, as ordinary dentine usually is. Pressure was made on this point with considerable force upon wet cotton, which gave no pain, proving that the pulp had entirely obliterated the exposure. The sensibility of the adjacent dentine was normal.

I had previously and have since not infrequently observed the distinct step inward to the secondary dentine as was observed in this case.

To-day the same tooth presented with a pulp exposure from caries on a proximate surface at the cervix, which was capped in the usual manner I now pursue.

I bring the case before you as one evidence out of many in my experience where there has not been the least indication of pulp degeneration. It has not been uncommon for those distrusting conservative treatment of the pulp to maintain that progressive degeneracy of the pulp tissue is a necessary consequence following

this mode of treatment. I may state here, it has been rare to find nodulation when subsequently the pulp has become devitalized. I am inclined to take this occasion to reiterate that, with correct precautions, pulp exposures previous to the occurrence of objective indications of pulp irritation is an entirely rational and generally successful method of treatment.

Question.—Will Dr. Jack give his experience relative to electric osmosis and what that experience continues to be?

Dr. Jack.—I have the satisfaction to state that the results continue favorable.

There is one important feature of the application of this means of giving relief from pain. This is in reference to the statement that the sensation produced by the current when the pain limit is reached is due to the evolution of heat in the tissue caused by the resistance of the dentine to the current.

In a number of instances I have made the test of applying five, ten, and fifteen chloride of silver dry cells. These are presumably of one volt each. In each case the pain limit is reached at the same degree of ampèrage. As current strength is the source of electrical energy this result is in agreement with electrical laws.

The pain limit appears with different persons at various degrees of ampèrage, according as the required resistance is varied; but more particularly for the reason that thermal irritation of dentine is a very variable condition. In other words, the temperature sense of the dentine differs in individuals.

The foregoing statements indicate that high voltage is not required, as only a certain degree of strength of current in milliampères will be tolerated. This can generally be forced into the tissue by a very small voltage rate. If the initial voltage be comparatively high, the resistance must be so great as to reduce the actual voltage to a tolerable rate.

There is one other important consideration connected with the application of electricity in cataphoresis, which is that the resistance of the controller at the highest part should be so extreme that no impulse is given at the commencement of the administration. At present I have in use a Willms controller, having a resistance at first of over three hundred thousand ohms. With this there is no initial impulse when the circuit is closed. With the former controller, having a resistance stated to be of ninety thousand ohms, some persons would feel the first contact with five volts of current. This question of the impulse of current is well elucidated by Dr. Price in an article to appear in the February number of the *Dental Cosmos*.

There is nothing more clear from my experience than the necessity for minimizing the electro-motive force at the commencement of the administration. The great value of this means of treatment is in some danger of being prejudiced by using high initial voltage with insufficient resistance. The apparent requirements are low initial voltage, probably ranging between five and twenty, with resistance commencing at two hundred thousand ohms or over. The purpose of this very high resistance being, as previously indicated, to avoid the initial impulse.

Dr. Roberts.—Dr. Jack's illustration simply proves that the voltage only is necessary to overcome the resistance of circuit; that the number of volts that we use does not make pain or lessen the pain. It is the amount of current or the ampèrage which passes through which does the work, and the voltage is only necessary to force the current through the resistance. If the five volts will produce the result, that is all that is necessary, or fifteen volts, if you have to use that ampèrage, there is no more pain when the same amount of current is going through it. It is not the voltage which gives pain, it is the ampèrage, in connection with the controller. I believe that a controller based upon the resistance and taken out is based upon the wrong principle. The voltage should be increased or decreased correctly and not the resistance, and that can be done.

Dr. Jack.—There is another point of importance not directly stated in this discussion,—that is, while some persons will indicate the pain limit being reached at a given point of the controller with an initial voltage of five cells, another person may not indicate the pain limit at the same point of the controller with an initial voltage of fifteen cells. In the one case the ampèrage will be less usually than three-twentieths milli, in the other three- or four-tenths milli.

Adjourned.

A REGULAR meeting of the Academy of Stomatology was held March 23, 1897, at the rooms of the society, 1731 Chestnut Street, Philadelphia, the President, Dr. James Truman, in the chair.

Dr. H. C. Register, chairman of the Clinic Committee, made a report, including his "Method of Operating."

CLINICAL REPORT ON METHOD OF OPERATING.

BY DR. H. C. REGISTER, PHILADELPHIA.

Individual methods of operating are of minor importance if they do not possess a qualifying reason why they are so done, embodying a "principle" that applies in all like conditions. That which is involved, as a principle, in the manipulation of gold as performed by myself on Saturday last, consists in adapting gold in regulated lamina, in opposition to an irregular form of cohesive work, and the fixation by forcing it to place by strips of bibulous paper or old soft linen, thus making a tight joint by packing the gold to every point of contact by the same effort, in opposition to retainers, cohesive and otherwise, which when done by instrument points are more likely to let some inequality remain, and also wound the finished tooth tissue, which is detrimental to the saving quality of the filling so far as it makes an inequality, thus preventing the hardening of the dentine beneath it.

The calcification of the fibrillæ, I claim, always takes place in forming a zone of secondary tissue in a filled tooth when the mechanical and physical relation are made compatible with each other to the exclusion of recurring exciting causes of caries. Metal fillings, through their thermal irritation, produce that result sooner than the zinc or gutta-percha. To this end the formation of cavities should conform to the natural cleavage of the enamel, which radiates from the stratum granulosum to the periphery, and, after Williams, are held together by the interprismatic cementing substance. An enamel wall, under the best conditions for its future preservation, should stand in this relation to the filling; the length of the enamel prisms, where possible, reaching from the enamel cuticle to the stratum granulosum, with the surface made smooth. In all cavities thus formed we get, as an anatomical result, a V-shape to a greater or less extent, this being always so natural as applied to enamel.

In connection with this, and all other forms of cavities, I can-

not lay too much importance upon the sterilizing and alkaline influence of bathing the cavities with iodine, and decomposing it and all carbohydrates and starchy matter, including germ-life, which is in the main composed of the latter material, and of placing the inner enamel and dentine in an alkaline or neutral condition before filling. The changes in the tissue, I believe, are as great as they are apparent, permitting and producing an antithermal change through secondary dentine more quickly, and anticipating the action of germ-life that may be left in the tissues.

The use of a matrix in connection with this method, and all others as well, should stand as a necessity only, in giving expression to the cavity,—*never a positive, fixed, artificial wall!*

As the environment of the tooth will be the exciting cause of future caries, the filling must anticipate, so far as possible, the dissolution of the interprismatic cement or the calcoglobulin, as pointed out by Williams, before a recurrence of decay can take place in any part of the filled border properly protected by the gold. To do this best is the aim of all honest operators. I present this method not as one of an hour, a day, or a month, but one that has stood the clinical criticism of fourteen years as a system, with the good work continuing to preserve badly broken-down teeth, as observed from carefully kept charts that tell the conditions then and now.

When one or more of the walls are broken, a matrix becomes a necessity, and here planished copper or German silver works best with me,—always fitting it to the individual case. This may be done by soft soldering the ends or using the silk ligature, which I generally prefer, winding it round and round the matrix to its width, which comes to the bulbous portion of the tooth only. To planished copper, which is rendered so pliable and dead by annealing, I give the preference for making all kinds of matrices.

If it is desired to give the filling an oval form or contour at the knuckling point of contact, it is only necessary to hold the copper strip, before cutting, in the palm of the hand or some fairly soft surface and burnish it to the extent required. The ligature takes it to place uniformly throughout the boundary-line and leaves a mould to be replaced by the filling.

Gold cylinders, the length of which correspond to the cross-axis of the cavity, are now laid on the bottom and sides and pressed to place by bibulous paper folded once, or to as many times as will correspond with the work in hand; and soft linen cut into strips is to be used in like manner without folding, and in its preparation

must always be cut, never torn. After the gold has been pressed to place under paper by "plugging pliers" (a special form is best), the ends of the cylinders are *turned over* and *around the cavity, between* the *tooth* and *matrix*, or the first cylinders may be placed and adapted under the bibulous paper, the edges of these turned over the border of the cavity at the cervix, and the matrix then applied as described, pressing against the cylinders, the operation being continued by the use of mat gold and malleted to place with the paper upon the gold, followed after its removal with proper small, smooth points until all parts of the boundary, as you progress, are filled *without the instrument coming in contact with tooth-structure.* After the enamel has been thus protected, to a greater or less degree, not being so essential as with dentine, the cohesive gold can be added wherever the masticating surface or contour calls for it. In the larger restorations the borders of the filling should be composed of cylinders carefully laid in contact with dentine and enamel throughout the joint contact in lamina. The centre or body may be filled in, however, with mat or crystal gold, as the air-spaces in the work are in no way detrimental. The time thus gained is all secured by the use of soft gold, it permitting about two-thirds of the cavity being filled in one-third the time, as a gain over cohesive work.

No special retaining device, as a rule, is necessary, other than a slight irregularity that may naturally exist; otherwise undercuts should be slight, and to see that the pounding and triturating forces of mastication are met by the cylinders being anchored as much within the body of the tooth as extending beyond the cavity in restoring the contour to any required form.

This method of operating, I believe, is in direct line with the latest discovery in histological research in its relation with the several anatomical parts of tooth-structure, both mechanically and physically related, and as a protection from the microgerm environment. Thus do we find non-cohesive or soft gold laid in lamina in juxtaposition against dentine and enamel, in contradistinction to small pieces being added cohesively in retainers, to be no veneer but of better grain, and being opposite in all its relations as a tooth-preserver, both physically and mechanically.

Dr. W. A. Capon gave a report of his clinic, exhibiting the preparation of a "porcelain jacket," as follows:

The case presented was a lady with deformed lateral incisors, commonly called "pig" or "rice" teeth, perfectly sound, with pulp

healthy; the bite unnatural through extreme prognathism; the lower incisors closing completely outside of the upper, thereby enabling me to give undivided attention to the crown alone. With such cases very little preparation of the tooth is required. Simply grinding both lingual and labial surfaces slightly flatter and short enough to leave room for thickened cutting-edge of porcelain. After this procedure the circumference of the tooth was taken with wire, the same as for gold cap, and the size cut from platinum plate, gauge 30, and bent in tubular form, joints lapped and soldered with pure gold. This tube was fitted to extend slightly under free margin of gum, and should be quite as long as the tooth. While the tube was in position I marked the outline of adjoining teeth on its surface to indicate the final shape. The lingual portion was ground to this line and then reinforced by soldering another piece of platinum of the same gauge to that surface. The labial surface was then ground sufficiently thin to allow of burnishing to the tooth, reducing the tube to a hollow wedge. This part of the operation is quite the most important and, I may say, the most difficult to perform, for on it depends the future of the crown and probably the operator's reputation with that particular patient. The platinum frame was then placed in position and a thin porcelain veneer adjusted on its surface and held by porcelain body. The whole was then gently drawn from the tooth and dried, ready for the furnace.

After fusing, the crown was tried in its place and found slightly prominent, which fault was easily remedied by grinding the surface. More body was then added to overcome the shrinkage of first baking and to give the crown its proper shape, then fired for the second time, giving the porcelain a uniform density and surface, restoring the original gloss destroyed by grinding.

After polishing the metal portion the crown was cemented in position, thus completing a crown natural in appearance, durable, and extremely applicable in this instance. No other crown can *artistically* overcome such deformities and still retain original form of the tooth, with pulp intact, unless it would be a gold cap,—and would that kind of an operation be a remedy?

The platinum was ground to form instead of cutting, so that a better joint is secured. The great heat in fusing would melt the solder from a flush joint and leave a crevice when finished. The same reason is advanced for lapping the joint when making tubes.

The furnace used was the Land "midget," one of the original gas furnaces, and still unexcelled for quickness and convenience,

requiring only five minutes to fuse continuous gum body from time of lighting.

Dr. H. E. Roberts gave a clinic on the bleaching of teeth by the use of pyrozone, aided by cataphoresis. The case was a lady with both centrals and the left lateral incisor badly discolored, the teeth having large approximal cavities. After having removed all decay and wiped out the cavities with a fifty-per-cent. solution of sulphuric acid, neutralizing the acid with bicarbonate of soda, three pieces of platinum wire were twisted together, allowing one end of each to be loose; these were put in the canals and tied there so that the bleaching could be carried on in all three at once. Then a twenty-five-per-cent. ethereal solution of pyrozone was diluted with water, the ether was allowed to evaporate, and the aqueous solution which remained was used to saturate the cotton which had been placed in the canals, the current turned on and gradually brought up to thirty volts, being kept there for one hour, when the lateral was found to be so much improved that the wire from it was taken out and placed in the other side of the left central, making two contacts in that tooth. This was allowed to remain about one-half hour longer, when the electric current was cut off. Cotton saturated with the pyrozone solution was then sealed in the teeth and allowed to remain for two days, when the teeth still showed a greater improvement.

Dr. Gilliams paper on "Some Dental Manifestations of Gout" followed.

SOME DENTAL MANIFESTATIONS OF GOUT.

BY J. S. GILLIAMS, M.D., D.D.S., PHILADELPHIA.

Any one familiar with the dental practice of thirty years ago will remember that occasionally the falling out of the teeth was said to be due to the gouty condition.

The cases in which this disease was observed were those which had a clear and direct family history of gout, the loss of the teeth mentioned as a possible effect of the constitutional disease.

The dental disorder called Rigg's disease was then, as it is now, regarded by many as purely local trouble. No one appears to search for a constitutional disease as an underlying cause. Some of the older books on dentistry and others on general medicine did hint at gout as a cause of dental periostitis, but not explicitly enough to make the connection between the two clear.

Such teeth were then, as now, suffered to be lost by the progress of the disease. Faint-hearted attempts at saving them were made by the use of clumsy scalers; the larger and visible deposits of tartar were removed and tincture of iodine applied to the gums and around the necks of the teeth. Occasionally a case would recover through this treatment, but usually the teeth were lost one by one.

In my own experience, it is only within the past score of years or so that any great number of patients suffering from this disorder have sought the services of the dentist with any hope of cure.

Most patients, as the teeth are lost by this disease, appear to suffer but little from dental caries, and were content to submit to the gradual loss of these organs, until a sufficient number were destroyed to demand replacement by artificial teeth, either for appearance or to increase the lessened masticating surface.

This type of cases presented to the dentist with the remaining teeth loose and the connecting and adjacent tissues soft and flabby has been due to pyorrhœa. This condition of the mucous membrane has been present after the loss of all the teeth, and there is left a flat mouth, covered by a more or less loose and flabby mass of soft tissues. The loss of the alveolar walls has destroyed the ridge of the arch, and the inflammation of the soft tissues has left a congested-looking mass, making a poor base for the support of a plate and teeth.

For some years I have noticed that patients who knew they had gout or rheumatism would complain of pain in or about one or more teeth whenever it happened they had an attack of the constitutional disease. Some of the teeth, in fact most of them, pointed out by the patient as being the seat of pain, would have no signs of caries, and no increased response to heat or cold. There would be some sensitiveness upon pressing or striking the tooth, but no marked signs of inflammation over the root. Occasionally the dental periosteum inflames, but rarely running on to abscess. Some persons having these symptoms, and who happened to be under treatment for gout or rheumatism, would have the dental disease disappear when the constitutional disease was cured.

Since the publications of Professor Peirce's essay and those of Drs. Kirk, Darby, and Burchard, I have examined more carefully the diseased teeth of persons known to have gout, rheumatic gout, or rheumatism. In all three of these diseases the teeth have been noticed to have pyorrhœa in some, erosion in others, and all of them

have been singularly free from decay. The teeth are usually the kind which appear to resist the causes of dental caries.

Besides the cases which are certainly gouty or rheumatic, there are others who have other general disorders diagnosed by their physicians, and who have pyorrhœa; the most common of these diseases is chronic dyspepsia. Many of the pyorrhœa cases in men are those addicted to the use of spirits, and others are champagne drinkers; many are gourmands. Others have, according to the testimony of their physicians, kidney or liver disorders.

The local appearances are so much alike in many of these cases that I am convinced, despite the diagnosis, that they would be found to belong to the gout family.

A number of patients who have never had an outbreak of acute gout or rheumatism will exhibit, upon close examination, some enlargement of one or more of the small joints, indicating gout or rheumatic gout which has not been diagnosed.

I have noted two interesting cases which will show the dental disorders which may attend the gouty or rheumatic condition. This first is that of a lady, aged about sixty years; five or six years ago she complained of an uneasiness in or about a lower wisdom-tooth. It was slightly sensitive to heat and cold, a little more to the heat than to the cold, I thought, and was a little sore to pressure or percussion. A beginning abscess of the pulp was diagnosed, and a broad gold filling which was in the masticating surface of the tooth was removed. The cavity was found not deep, the dentine hard, and the sensitiveness normal. The cavity walls were bathed with carbolic acid and oil of winter-green, and filled with cement. My friend, Dr. Burchard, saw the case and, after questioning the patient closely, diagnosed it as probably a local expression of rheumatism or gout, very probably the latter, and referred her to her physician, who placed her upon treatment for obscure gout; her general discomfort vanished and so did the dental trouble. Since then she has had one or two attacks of gouty trouble, and the dental disease broke out again and disappeared with the cure of her gout.

The next case is the one reported at a meeting of this Academy in 1896.

A lady of middle age, who had well-formed teeth and but little caries, complained of pain and swelling over two front teeth. These teeth had no cavities and had live pulps. The only cause of trouble seemed to be that they struck the lower teeth a trifle too hard. The tips of the lower teeth were ground off, the gum painted

with iodine and aconite, and in a few days the pain disappeared. After a time she called again and then had swellings over these roots; between the swellings and the necks of the teeth the gum appeared to be healthy, and there were no deposits under the edge of the gum.

The patient has a family history of rheumatism; her sister having been a rheumatic, and had lost teeth by this variety of exfoliation. Tartarlithine was prescribed, and the inflammation subsided. In a few weeks she returned, and the swellings looked like abscesses; at the same time she complained of pain in some of her muscles. The swellings were opened and the process found partially destroyed, but there did not appear to be any deposits. With the cure of the rheumatism the dental trouble ceased. The loss of process is gradual and the teeth are getting looser, but the antigout treatment seems to retard the loss.

A third case is that of a physician who had lost several teeth by the process described by Dr. G. V. Black, in the "American System of Dentistry," as phagedenic pericementitis. These attacks occur after he has had trouble with his liver. He says he has never had gout, but he exhibits all of the indications of a person suffering from faulty elimination of waste products.

THOUGHTS ON REGULATING.

BY HOWARD E. ROBERTS, D.D.S., PHILADELPHIA.

Mr. President and Gentlemen,—My excuse for writing this paper, if an excuse is necessary, is that I was asked to do so.

My reason for taking this subject is that I believe I correct irregularities somewhat differently from the majority, and with results gratifying to myself and apparently satisfactory to my patient. When I say gratifying to myself, I mean that I accomplish that which I attempt with the least worry about keeping things in place and without the necessity of having a laboratory handy. Satisfactory to my patient because there is the least amount of suffering with the greatest amount of comfort possible while going through an uncomfortable operation.

Apart from the annoyance of having the teeth sore, a great deal of irritation and worry is caused when anything is placed within the arch that either interferes with the free use of the tongue in talking or eating or that the tongue can play with or move. The patient is continually under a nervous strain and "mole hills seem

like mountains," therefore I keep my appliances as much as possible upon the labial surfaces of the teeth.

Another great source of irritation comes from ligatures or bands either pressing against the gum or slipping out of place and working up around the neck of the tooth, therefore I see that it is impossible for them to get out of place. Keep things out of the way of the tongue and ligatures and everything else from touching the gum, and you have gone a long way towards making regulating bearable to the patient.

It seems almost unnecessary to say that all appliances should be made as small as possible. The appliances for nine-tenths of the cases of irregularity which are presented for correction can be made at the chair, and the only special instrument necessary is a jeweler's jam-plate for cutting threads. The jam-plate is not made mechanically to cut a thread, but, as its name implies, to jam or indent a thread upon a wire. It will do its work nicely and easily if care is taken to make the wire square where the thread is to be cut; to jam a thread upon a round wire is sometimes difficult.

A set of dies and taps can be procured, if it be desired, which will cut a thread perfectly; the wire or pin must be round, or nearly so, where these are used, and not square as in using the jam-plate.

In this set of four dies which I use the threads run 80, 100, 120, and 140 to the inch, and the one most used is 100. You can see the size of the wire upon which the thread is cut. With the dies there come taps to match. In using the jam-plate I make the tap I need from an old excavator.

I can best describe my mode of treatment by taking a case in practice, and have selected one where the teeth are somewhat jumbled. I do not attempt to do the work rapidly, but as comfortably as possible. In this case the corrected upper jaw is not a perfect arch, as the patient's parents did not care to carry it further, and the left lateral is a malformed tooth.

When this case was first presented an impression was taken in modelling compound of both jaws so as to show not only the teeth, but the gums over the roots of the teeth. I have never found it necessary to take the impression in plaster, and it would seem to be a waste of time. Always date and preserve the casts of the teeth as they are, before starting to make the correction, and study them carefully before going further or giving any advice.

An engagement was made on April 20 to make and put in place the appliance on the upper jaw. Previous to the patient coming, I provided a piece of platinum plate of thirty-two gauge to

make bands from and a piece of half-round platinized gold wire which would reach from the first bicuspid on one side to the corresponding tooth on the other when resting upon the labial surface of the teeth, this made a spring bow. The ends were filed square for about three-eighths of an inch and threads were cut upon them with the jam-plate. To make the little nuts for the screw ends of the bow, the temper was drawn from an old excavator, the end filed square and the same thread was cut upon it, when it was retempered to a straw color; this made the tap. Holes were then drilled through a piece of heavy gold plate and tapped; small pieces were cut from the plate having the tapped holes in their centre, these were again run upon the tap to hold them and filed square, making them as small as possible for strength. This bow was made before the patient came. The canines required spreading, and with the patient in the chair a strip of platinum was cut one-eighth inch wide and three-eighths inch longer than the circumference of the tooth, bent in the form of a U and forced between the adjoining teeth and the canine with the ends out. With the finger hold the piece firmly against the palatine surface, then with flat-nosed pliers, which are smooth in the beak, grasp the two projecting ends, and, bearing upon the face of the tooth, close the pliers firmly, when you will produce a band closely fitting the tooth with the ends projecting at right angles, the bend being sharp and square. Cut one end off one-eighth inch from the band and the other one-fourth inch, bend the longer sharp, to fold over the shorter end and squeeze with the pliers, which clamps the ends together. Put a piece of pure gold over the joint inside the band and flow until the lap is thoroughly soldered. The annealing lamp will give heat enough. A band is thus made having a stout lug upon the face, through which drill a hole large enough to pass the end of the bow freely and file or grind away the excess of material to make a finished band and loop. This band was cemented to one canine and a similar band was made and fastened to the other.

The nuts being in place upon the bow, it is sprung into the bands and should rest upon the face of the most prominent incisor, which was ligated firmly to the bow and the nuts screwed against the loops on the bands; this was allowed to rest quietly for three or four days to allow the patient to become accustomed to it, after that the other incisors were either ligated to the bow or were drawn to it with rubber bands and the nuts were kept tight against the bands on the canines. On April 28 the same kind of an appliance was placed upon the lower jaw and both jaws straightened at the same

time. I saw the patient nearly every day from that time until May 23, when she left the city; afterwards I saw her on June 10, 16, 26, and 27, July 10, 11, and 13, on which date I placed retaining bands on both upper and lower teeth, less than three months from the start, and the total time devoted to the case was twenty-nine hours. At no time did she complain of the pain, her gums were never inflamed, and she always came in smiling and seemed rather to enjoy the operation, as she was interested in it.

I have straightened teeth in the mouths of patients from seven years to forty years of age, and for ease and comfort I would take from fourteen to seventeen years, older rather than younger, and if a case is presented with the canines not erupted, as a rule, I would say wait until I can get bands upon them. If both parents and patient are not anxious to have the teeth put in place and be willing to assist and give the time to it, I would also say wait, they will probably want it done later when it will be easier for all, and particularly for the dentist. If asked how long it will take, I double the time I suppose will be necessary, and tell them that long; it is better to be through sooner than to take longer than they expect.

I believe a mistake is frequently made in thinking a case too easy and proper appliances are not made, the result being disappointment and failure.

In putting a bow in place it should rest naturally over the teeth near the gum and not spring towards the cutting edge; if it does, the tooth to which it is ligated may be elongated. If the ligature has a tendency to work off the tooth, drawing the bow down, make a band for the central and file a notch in the projecting lug, into which the bow will drop, and cement it to the tooth. To keep a rubber band or ligature from getting out of place, cement a platinum band near the tip of the tooth and tie the ligature just above the band; the band keeps it from slipping off and the tooth is larger above so that they cannot work up.

To make a band with a hook, over which to slip a rubber band or ligature, bend the lug over and file into shape. No metal band should be placed around a tooth without being thoroughly cemented. When a nut works loose, a ligature around the bow, over the nut, and hooped over the end of the bow and tied, will keep it in place.

I use the force of the screw, the spring of the bow, the elastic band, and the stress of a ligature tied tight all at once, or one at a time, as seems most desirable. It seems difficult to give good working advice, about a case from looking at the casts, because each case has an individuality of its own. The patient should be seen

and known, and the ability of the dentist to carry out suggestions should also be taken into account.

For remuneration, I prefer to keep a record of all time spent upon a case and charge by the hour.

I do not like piano-wire for springs, or silver or German-silver appliances; they are unsightly; gold and platinum for a case does not cost much and are very much nicer.

I have found the vulcanite plate in the roof of the mouth an excellent thing upon which to become proficient in the use of profane language.

DISCUSSION.

Dr. Darby stated that he had seen so many similar cases that it seemed to him pyorrhœa must be associated with the gouty diathesis, although in some cases of calcic pericementitis and erosion gout is not evident, but there seems to be a strong probability of manifesting itself at a later period; also in very aggravated forms of gout there may be an entire absence of dental trouble, as an instance, a lady who was suffering from an inherited case of gout, and who for years had been compelled to be under a rigid anti-gout treatment with but partial relief; but, fortunately, she was entirely free from pyorrhœa alveolaris.

Dr. Register.—I believe pyorrhœa to be a manifestation of the gouty diathesis, having had personal experience in the matter, entailing the loss of a lateral incisor; although most authorities credit the young with being free from pyorrhœa. I have a patient, fifteen years of age, presenting that condition, and whose family history shows gouty tendencies, his father having died from rheumatic fever.

Dr. Roberts.—Gout may manifest itself in many ways, and although there may be no other symptoms than that of pyorrhœa, I believe some time there will be other indications of a gouty condition.

Dr. Jack.—I would like to ask if any one can assign a cause for the receding of the gums and the absorption of the alveolar process when there is no evidence of a calcic deposit or inflammation of the parts?

Dr. Truman.—There is apparently a condition frequently met with, and as often overlooked, that seems to answer the description of Dr. Jack's query. It is recession of the gums without any of the symptoms of pyorrhœa.

This is not confined to old age, but may present at a com-

paratively early period, from thirty to thirty-five. In a case coming under his care, at the latter age, all the teeth were more or less affected by resorption without any of the ordinary signs of pyorrhœa. On examination, microscopically, of one of the teeth thrown out by the destructive degeneracy of the tissues, it exhibited a nearly complete eradication of the tubulated structure. So marked was this that the section presented the appearance of a transparent plate of glass. The question of calcification of the inner tubular tissue was then in warm dispute, and as it was difficult to determine the cause of the obliteration of the tubuli, it was left then without explanation. The only reasonable conclusion, however, is that the teeth had become practically foreign bodies, and were thrown out as organs incapable of proper nutrition. Senile dentine—dentine of old age—may and doubtless does produce the same effect.

Dr. William H. Trueman.—There is always a tendency for teeth to assume their proper position in the arch; so I want to particularly commend Dr. Roberts for his remarks about waiting until we are sure nothing further can be gained by delay. The tendency of teeth to return to their former position is a very serious condition we must recognize in regulating, and unless they can be fixed in the new position our labor will be lost.

Dr. Register.—I want to commend Dr. Roberts for the valuable suggestion he has given us in his method of regulating; it is unique, simple, easily constructed, and efficient.

Dr. Gardiner.—I have seen most of the cases of Dr. Roberts for the past seven years, and I cannot but express my pleasure in the way he handles his cases of regulating.

Subject passed.

A CHAPTER IN DENTAL HISTORY AND BIBLIOGRAPHY.

BY WILLIAM H. TRUEMAN, D.D.S., PHILADELPHIA.

Having been apprised of the fact that Dr. Kirk would give us to-night a *résumé* of Dr. Williams's work, exhibiting the latest achievements in the microscopic study of tooth-structure and of tooth-destruction by caries, I thought it might be of interest to take a glance backward, and have brought with me the works of Alexander Nasmyth, who was, I think I may safely say, the first of our profession to earnestly take up this line of investigation. Early in the thirties he began, as all careful and methodic investiga-

tors should, by first collecting, collating, and critically comparing all the accessible works of those who had preceded him, and thus made himself master of that which the world knew in this selected field. His industry and thoroughness in this preparatory work is commendable and well worthy of imitation. I show you a copy of Serres's work,[1] once the property of Mr. Nasmyth, with notes and pencillings made by him while prosecuting this study. The first results of his labors are embodied in this volume, "The Historic Introduction to Nasmyth's Researches on the Development, Structure, and Diseases of the Teeth," published in London in 1839. Its perusal will be a revelation to any one who imagines that dental literature prior to that date did not amount to much. Both in quantity and value it was such that no profession, however exalted, need hesitate to acknowledge it. I would that it were more accessible and better known.

Next, we have the beginning of his original work, this little volume of some sixty pages with nine plates, his "Three Memoirs on the Development and Structure of the Teeth and Epithelium," published in 1841; and lastly this, Nasmyth's "Researches on the Development, Structure, and Diseases of the Teeth," published in London in 1849, the conclusion of his labors, the manuscript of which he had barely completed when he was suddenly, in the midst of his usefulness, stricken down and incapacitated for labor. Valuable as this work is, it would undoubtedly have been more so had he been spared to superintend its publication.

These three volumes, the life work of Alexander Nasmyth, which has made the demonstration of this evening possible, were the beginning. The work of Dr. Williams shown us to-night by Dr. Kirk is the highest point so far reached as the result of sixty-five years earnest, continuous work of many enthusiastic laborers, who at every stage brought to bear the best that science and skill of the hour afforded in solving the mystery of tooth-building and tooth-destruction. In passing we may note for a moment that Nasmyth's time and Nasmyth's work may serve as a dividing line between the time when much that was accepted as truth rested upon theory alone, and the time when, as Nasmyth remarks, the advance in optical science rendered demonstration possible. Very early in his investigations Mr. Nasmyth was compelled to halt. The best microscopes and microscopic accessories attainable he found far too crude for the delicate work he had in hand. Enlisting the aid of expert

[1] L'Anatomie et la Physiologie des Dents, par A. Serres, Paris, 1817.

opticians, partly by his suggestion and partly by his own mechanical skill, he initiated a series of improvements which has made the microscope of to-day the marvellously precise instrument it is.

Eustachius wrote in the little book we examined together a few months ago, published at Venice in 1563, that if the germs of the permanent teeth are not seen in the fœtus, it is not that they do not exist, but that they are too small to be recognized. The microscope has enabled us to see with the eye that which this learned writer saw only in mind. Again, John Fuller, on page 55 of this little volume, "A Popular Essay on the Structure, Formation, and Management of Teeth," London, 1810, a work which, judging from the frequency it is referred to by his contemporaries, was held in high repute in the long ago, while discussing the phenomena of tooth-decay and its causation by some acidity of the surrounding fluids, cautiously suggests that the reason why it attacks certain spots in preference to others equally exposed, may be due to some congenital modifications of tooth tissue at that particular point. This haltingly made suggestion, Dr. Williams eighty-six years later demonstrated to be correct.

How slow, even in this progressive age, is real progress. It took some forty or fifty years of well-directed microscopic work to solve the mystery of dental caries. Nearly a decade and a half has elapsed since Dr. Miller announced that dental caries was the result of microbic energy, the initial stage, however, baffled his keenest scrutiny. Dr. Williams, by steady and patient work during the intervening years, aided by the improved facilities advancing science has supplied, seems to have completed the work, and we may now, for the first time in the history of our science, say that this riddle of the ages has been solved. So far, however, the stumbling block to the practical application of this discovery still remains. It seemed easy, after the discovery was made, to *prevent* instead of *repair* the ravages of dental caries. You may remember that Dr. Miller, and others, earnestly and hopefully began work to compass this desired object, only to find that an efficient germicide was also an equally efficient homicide. So long as this is the case, prevention remains a dream.

While we are looking backward permit me to call your attention to two other books I have with me. First, a well-preserved, handsomely bound copy of the "Elements of Odontology," by M. Lecluse, a surgeon dentist of Paris, dated 1754. Lecluse was a dental writer of well-deserved repute. This volume contains two of his works; the first is mainly upon the anatomy of the mouth and its surround-

ings, touching briefly upon some diseases of the gums and teeth. I particularly call your attention to the second plate, page 131, representing three instruments devised by him for removing deposits from the teeth, especially a double-ended one, one end shaped for a push cut and the other for a draw cut. They are quite unlike the cumbersome instruments for this purpose so frequently figured in dental books. I have no doubt but that these instruments, devised by Lecluse nearly a century and a half ago, for delicacy and convenience would fully meet the approval of the most exacting of to-day, while his directions for performing the operation of cleaning the teeth, so far as the mechanical part is concerned, leaves little to be desired. Bound with it is a work he wrote a few years before, intended for the use of the public, on first and second dentition. It had been so well received both by the public and his professional brethren, he tells us, that to extend its usefulness he has included it in this work, intended mainly for professional readers. A careful study of dental literature fails to confirm the idea, so often expressed, that our profession has been remiss in the matter of instructing the masses in the care of the teeth.

This little work by Lecluse is but one of hundreds written by dentists with that object in view. To emphasize that fact I show you a copy of the very oldest dental publication at present known, possibly the only one in existence of so early a date, printed at Meyng, by Peter Jordan, August, 1532. It is entitled "Zene Arzney," and is a beautiful, well-preserved specimen of the antique German. Its scope and character is well shown by the title-page, translated as follows: "Teeth Medicine: against all kinds of defects and diseases of the teeth; many wholesome and well tried medicines extracted out of the books of Galen, Avicenna, Mesue, Cornelius Celsus, Pliny, and others; together with compendious and useful instructions as to how one can keep his teeth healthy, and how one can extract the bad hollow teeth, or their roots, which get to paining easily." A translation of a later edition will be found in the *Dental Cosmos*, vol. xxix., January, 1887, p. 1, and on page 68 of the same will be found a history of the copy there translated. In that history it is stated that when Mr. Crowley compiled his dental bibliography, in 1885, the only information of this book was a reference to it in a German medical journal issued about one hundred years ago, giving the date 1536, and place of publication Frankfurt. Shortly after the publication of Crowley's work a copy was found, and became the property of the *Dental Cosmos*. This was printed by Christian Egenolff, at the Leather Breeches (Ledderhosen),

Frankfurt, 1541. The copy I show you bears the imprint of Peter Jordan, at the "Leather Breeches," Meyng, 1532, nine years earlier, and Crowley's No. 15 is, I think, another edition under a somewhat different title, dated at Erfurt, 1614. In the Index Catalogue of the Army Medical Library at Washington, vol. xvi. p. 766, 1895, is noted a reprint, in 1891, by C. Weigler, of Berlin, of the little book I show you. So much for its history. For the contents I refer you to the translation in the *Dental Cosmos*, it is well worth reading, and old as it is may furnish a model for those who propose a series of popular treatises upon dentistry for the Sunday newspapers. The last admonition, if properly emphasized, might tend to make them popular,—"And finally, after eating, always wash the mouth with wine or beer." Further than it refers to filling cavities of decay with gold leaf, and thus carries back the use of gold for this purpose to at least 1532, this little book has value only as a curio, and as a well-preserved specimen of typographic art as it was three hundred and sixty-five years ago. It belongs to a class of publications of that period and later, of which a few specimens survive, devoted to matters of health and the toilet. Jordan and Egenolff were printers or publishers, not writers; the later name I find in connection with another work of a similar character, in Latin, of nearly the same date. In conclusion, from 1532 down to 1897, there never has been a time when publications giving popular instruction for care of the teeth were not accessible to the public; many of them have been well written, and, on a whole, in my judgment, those that I have seen compare favorably with the best of their time in any science or in any art.

Adjourned.

A REGULAR meeting of the Academy of Stomatology was held in the rooms of the society, 1731 Chestnut Street, on April 27.

The proposed amendment to the constitution—viz., that the council of the society shall consist of six instead of five members, as heretofore—was voted upon and passed.

Dr. Thomas called attention to a deficiency of the subscription-list for the placing of an heroic bust of Dr. Horace Wells, the discoverer of anæsthesia, in Washington, D. C. Although the appeals to the profession at large for subscriptions had met with a prompt and generous response, the sum total is still insufficient to provide the proposed memorial. Other dental societies, as well as the dental fraternity in general, had subscribed, and Dr. Thomas urged that the members of the Academy subscribe again to so worthy an object as perpetuating the memory of one of the world's greatest benefactors.

The Clinic Committee reported an exhibition of a case by Dr. Louis Jack, upon whom he had performed two operations in the same mouth, which might be fittingly termed the reimplantation of teeth.

Dr. Jack.—The case herewith presented is one in which correction of a deformity and cure of a diseased condition have been accomplished by means of radical surgical measures. The case is described in my paper upon "Plantation of Teeth," *Proceedings of the Academy of Stomatology*, December, 1895, as number two of the replantation cases. (See INTERNATIONAL DENTAL JOURNAL, vol. xvii. p. 139; also *Dental Cosmos*, vol. xxxiii. p. 189.)

The patient, a female. About three years before, the upper incisor teeth fell victims to phagedenic pericementitis. The disease began in the lateral incisor of the right side, and subsequently the central incisors became involved; following upon this the left lateral incisor has become displaced.

The early clinical stages of the disease change in the positions of teeth; what is known as voluntary tooth-movement affected markedly the right lateral incisor to an extent productive of positive deformity, the malposition of the central incisors being not so marked.

As a means of correction it was contemplated and advised that the affected teeth be removed and replanted in their normal positions. To this the patient demurred, but consented that the operation be performed upon the tooth most out of alignment,—viz., the lateral incisor. As there was evidence of disappearance of a por-

tion of the partition of bony tissue between this incisor and the adjoining central incisor, it was urged that the operation be performed upon both teeth, to which the patient would not assent.

She was etherized, the lateral incisor was extracted, its canal cleansed and filled with gutta-percha, and placed in an antiseptic solution. The existing abnormal alveolus was extended at its lingual aspect, and deepened, until by measurement it was shown that it would permit the placement of the tooth in correct position, —that is, virtually, although the tooth was replanted, a new socket was formed, so that the operation actually resembles implantation. The sterilized tooth was placed in position and retained immovably by means of a fixture for a period of six months, when the tooth was found to be perfectly firm in its new socket, and upon percussion exhibited normal resonance.

The malposition of the central incisors became so marked that operation upon them was deemed imperative. By this time the pocket upon the distal wall of the root of the right central incisor was extensive, exhibiting a loss of at least a portion of the adjoining wedge of alveolar process. The roots of these teeth were immersed in a dilute solution of hydrochloric acid (after the method of Dr. Amoedo), but not carried to the extent of decalcification advised by him, the purpose being to remove any minute deposits of calculi which had escaped detection, as well as to soften the cementum which had become exposed by the extension of the teeth.

The retaining appliance (see illustration) consisted of a narrow gold plate clasped to the bicuspid teeth; a tongue of the plate extended over the lingual face of the replanted tooth, through which two holes were drilled near the neck portion; an extension of the tongue, as shown, was carried over the cutting edge of the tooth. Through the openings a fine platinum ligature was passed, and the teeth were lashed to the plate to maintain their position laterally. The illustration shows the fixture adapted to the retention of three teeth.

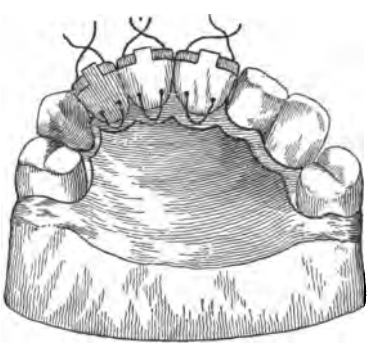

The splint for the fixation of the lateral was kept on for six months, but in the case of the centrals, at the end of four months the teeth were found firm in their sockets. Upon percussion the

teeth exhibit normal resonance, except the right central incisor, that in which the degenerative changes accompanying phagedenic pericementitis were marked; this tooth responds with a dull, flat note when tapped, indicating an inferior density of the surrounding tissue in comparison with the two other replanted ones.

The gum festoons about the necks of the teeth exhibit a normal appearance, there being no evidence that the teeth have undergone operation. In addition, the crowns of the teeth are translucent, appearing as though they contained vital pulps.

The remaining lateral incisor is now involved, which will necessitate, in the near future, operation upon that tooth also. This operation is of interest as exhibiting the possibility of radical relief in the early stages of phagedenic pericementitis before atrophy of the alveolar walls occurs.

DISCUSSION.

Dr. Guilford.—I examined the case, and think it a pronounced success; the teeth are firm, and there is no evidence of operation upon the crowns or the roots of the teeth.

Dr. Roberts.—What is your opinion, Dr. Jack, of the mode of union in these cases?

Dr. Jack.—Histological data are deficient in this connection, but, combining such data as we have with reasoning upon pathological and physiological teachings, it appears to approach in nature an encystment, having the characteristics of ankylosis.

Dr. James Truman arose to a personal explanation. At a former meeting his remarks on Dr. Williams's slides were misinterpreted, and were made to appear as in opposition to Professor Miller's views on dental caries. Such interpretation was not warranted by anything then stated, and was widely at variance from his own views. His criticism, at the meeting mentioned, was confined entirely to two or three slides in the collection. The preparation of these, as well as all exhibited, was beyond criticism, but the deductions sought to be drawn from them were not, in his judgment, correct. He then proceeded to give his ideas in a manner to avoid misconception.

The President.—The papers of the evening are now in order,—the essay of John Girdwood, D.D.S., L.D.S., Edinburgh, Scotland, upon "Root-Perforation: A New Method of Treatment," and a short report by Dr. Henry C. Register upon "Some Features in Bridge-Work."

ROOT-PERFORATION: A NEW METHOD OF TREATMENT.

BY JOHN GIRDWOOD, D.D.S., L.D.S., EDINBURGH, SCOTLAND.

Among those of our profession to whom modern dentistry is something more than a mere expression, the title of this communication is bound to elicit interest. The man whose daily work is conservation and not substitution, who "crowns" and "bridges" undeterred by anything so long as he has faith in those lines of treatment and in himself, will see in it an attempt to cope with a real difficulty, which will, however, not be so apparent to him whose methods of practice are not strictly modern.

Whether perforation be the result of traumatism or of caries; or be situated in the side of a single root; at the bifurcation of two or more roots; or have travelled down the side of a fang from a supragingival cavity, it is at present deemed a condition so serious as to make the success of any remedial measures very doubtful. If we examine the literature on the subject its meagreness seems to express a certain shyness in handling the treatment of so uncertain an issue, and what there is of it practically admits that the methods advocated are seldom, if ever, successful.

The varieties of perforation may be roughly divided, according to their causes, into two classes:

First. Traumatic, accidental in root-drilling.

Second. Carious, as the result of caries.

The traumatic variety is usually deep in the root and small in area, and is the more amenable to treatment if undertaken soon enough to prevent intrusion of the pericementum into the canal or cavity. The second variety generally occurs about the cervix, and is often very extensive. When perforation of either kind occurs it is followed, as indicated above, by intrusion of the soft tissue subjacent—hernia pericementi—and by pain more or less continuous until the sharp edges of the aperture have irritated the intruding soft mass till it becomes inflamed and gangrenous, sloughs, or gives rise to abscess.

The method of treatment most generally followed is that described by Dr. Evans in his book "Crown- and Bridge-Work," and which I shall briefly quote. "Inject the canals with peroxide of hydrogen, then bathe with alcohol, dry with hot air, and fill the canals closely, but not tightly, with cotton saturated with oil of cloves and seal with gutta-percha. Renew the dressing at intervals,

preventing the entrance of saliva until the exudation of serum ceases at the perforation, and a film of cicatricial tissue has been formed. Dry the canal thoroughly and fit closely over the perforation a small, flat piece of gutta-percha warmed and applied with a gentle pressure sufficient only to produce adhesion without forcing the gutta-percha through.

"Previously painting the adjacent walls with chloro-gutta-percha will cause the gutta-percha to adhere readily," etc.

While I believe this method may sometimes prove successful where the operation of filling only is required, it is altogether unsuitable in the front teeth when these require to be "crowned." Moreover, the application of a piece of gutta-percha as described is a matter of extreme difficulty, except where the perforation is near the gingival end of a root, and, even when successfully done, the well-known property which gutta-percha possesses of swelling in the presence of moisture is certain, sooner or later, to produce the inflammatory changes leading to abscess of a nature almost incurable, because of the difficulty found in the removal of the cause except by extraction of the tooth. Other methods than the above have been tried, such as shaping a piece of quill, or a section of gold tube to cover the opening, but all of these—which may be summed up as partial intubation—are open to the same objection. They are all, moreover, liable to displacement when a post has to be used in "crowning."

It is obvious, therefore, that for the successful treatment of perforation we require a material essentially different from anything of the kind up till now recommended. It should be sufficiently plastic to adapt itself readily and accurately to the tissues underlying the lesion without danger of displacing them; it must be non-irritant and insoluble, capable of becoming hard and resistant within a reasonable time, and of bearing considerable pressure without fear of movement or fracture. Such a material we possess in copper amalgam. Besides having the qualities already enumerated, copper amalgam is markedly antiseptic, a property of no small value in this connection, while the astringent action of its salts in allaying early inflammation are too well known to need comment here. Its application, which is nothing more or less than entire intubation of the perforated section of the root, is given in detail in the following cases:

My first case of traumatic perforation occurred about six years ago, in a right upper lateral incisor, which I was called upon to crown. The root had been filled some years before with gutta-

percha. This I drilled out to what I judged to be about three-fourths the depth of the root, which, at this point, seemed to take a bend to the left. Having reamed out the canal, and fearing it was not quite deep enough to accommodate the pin, I unwisely proceeded to drill the canal a little deeper. I had almost succeeded to my satisfaction, when the patient showed sudden signs of pain, and on withdrawing the drill, wiping out the canal, I found traces of blood. I immediately dried out the canal and carefully dressed it with oil of cloves. Next day the case showed a distinct swelling on the gum over the seat of the perforation, but within three days this swelling had entirely disappeared and all irritation had subsided. At a subsequent appointment I removed the dressing, dried the canal out thoroughly, and proceeded to seal the perforation in the following manner:

Having mixed copper amalgam quite thin I gently carried a small portion of it to the apex with a blunt-pointed instrument rounded at the end,—in fact, an old excavator with the point broken off. The amalgam was gently spread round the upper portion of the canal, a rotatory motion being used to carry it evenly around the interior. No pain was caused by this proceeding, but the patient was just aware of a very slight sensation while it was being done; this sensation subsided when the point was withdrawn. The interior of the canal being thus lined, its depth was not seriously lessened. The patient was now dismissed till the following day, when the amalgam had hardened thoroughly, and at the next sitting a Richmond crown was set, and has done good service up to the present time.

The next is a case of traumatic perforation of a different nature, near the apex of a second upper bicuspid root, in the mouth of a lady for whom I had, four years before, treated an extensive perforation at the bifurcation of a second lower molar, right, now crowned and doing good service.

Miss M. called about fourteen months ago and desired me to crown the left second upper bicuspid.

The tooth had been filled some years previously with copper amalgam by another dentist, and as it had become gradually more and more discolored she determined to have it crowned. I removed the filling and found the pulp alive, I destroyed and removed it with difficulty, the canal being long, flat, and contracted.

This last was then opened up with Gates-Glidden drills and the apex sealed. I now proceeded to enlarge the canal with Peeso's small-sized reamer, which I consider by far the best and safest

instrument for this purpose. Having nearly succeeded in enlarging sufficiently for the Logan crown I meant to fit, and when I was using the medium-sized reamer and drilling slowly, the patient showed signs of pain; the drill was at once withdrawn and chips blown out. Suspecting perforation or a near approach to it, I wiped out the canal, but found no sign of blood. I now cautiously explored the whole canal with a stiff, hooked Donaldson bristle and found a tender spot quite close to the end of the root, which I cautiously pressed upon. Immediately the patient showed signs of pain. I now wiped out again and saw this time a tiny drop of serum on the cotton. Having swabbed out the canal with carbolic acid and dried thoroughly, I sealed the perforation with copper amalgam as in the former case. In this case there seems to have been no actual perforation by the reamer, but the wall was so thin that it would no doubt have yielded to the pressure of the cement during the setting of the crown, so that in all probability the actual perforation by the exploring point was the means of avoiding a more serious accident, for had I proceeded with the setting of the crown, there is little doubt that the thinned wall would have been bulged outward, and irritation set up of such a serious kind that successful after-treatment might have been impossible.

In the treatment of carious perforation—the second variety—I have followed similar lines as shown in the following cases:

Mr. H. called about three years ago to have some teeth filled. On examination the left upper lateral crown was missing and the root almost entirely covered by gum. I proposed he should have it crowned, but was informed that this had been twice done about two years before, and that each crown had failed within a few days of its insertion. This had proved so discouraging to the patient that he decided to let it alone. About a year ago he again presented himself and requested an effort should be made to crown.

A thirty-per-cent. solution of cocaine was applied to the hernia-like knuckle of gum occupying the face of the root, and when this had been removed as completely as was deemed possible, a long, funnel-shaped opening was seen. This was washed out, and when bleeding had ceased was packed with cotton dipped in oil of cloves and hydronaphthol and lightly sealed with temporary gutta-percha. In twenty-four hours this dressing was taken out and the walls of the root explored; these were found to be extensively softened and perforated on the left side well below the gum, which projected through the space. At the apex—sealed at previous crownings—

about one-eighth of an inch of the normal canal was patent, the remainder being hollowed out as just described. The carious dentine was now cautiously removed by a spoon excavator and the perforation unavoidably enlarged, till, on the left side, it extended from the gum margin towards the apex for fully a third of the root's length, and a new perforation of a like size was made on the right side: thus of the gingival circumference only the lingual and the labial parts remained. This sacrifice, however, brought me to comparatively healthy dentine. The cavity was packed as before and the patient dismissed. At the third visit all traces of decay were removed and the interior of the root roughened for retainage. After careful drying out the soft tissues surrounding the perforation were lightly touched with carbolic acid to prevent ingress of serum and again dried with hot air; copper amalgam was made very thin and plastic, and a little of it gently placed over the perforations and spread over them and their adjacent dentine edges with a round, straight instrument used with a rotatory and rolling motion. In the apex I now placed a smooth iron post, which had been thinly coated with wax,—it was merely heated, plunged in wax, and then cooled,—and round it tamped copper amalgam till the canal was full. Next day this post was heated, the wax melted, and the pin almost dropped out. I then mounted a Richmond crown, which during the three years which have elapsed I have repeatedly seen, and which the patient assures me has never given a moment's trouble or discomfort.

In the spring of 1894, Mrs. M. presented herself at my office. An examination disclosed the right lower first molar abscessed, and with a small polypoid projection of gum growing from the bifurcation of the roots and projecting into the large carious cavity of the crown. Inquiry elicited that the tooth had been crowned some time before she came to me, but the crown had only remained on a short time, and had given rise to almost constant pain till it, fortunately, came off and gave her relief.

Having cleaned out the cavity as thoroughly as possible, I anæsthetized the polypoid portion of gum and cut it off. The decay around the margin of the cavity was thoroughly removed with large spoon-shaped excavators. Free hemorrhage ensued and was checked with hot water as in the other cases. A light dressing of cloves and hydronaphthol was next applied, and the patient dismissed till the following day. After the roots had been treated and filled, the perforation was touched with carbolic acid, thoroughly dried, and soft copper amalgam gently plastered over the whole in-

terior of the cavity, anchorage being got by slight undercutting at the sides. A gold crown was mounted on the root, and has since done excellent work.

In another mouth and about the same time I discovered a type of perforation very commonly met with. The left upper second bicuspid presented an almost hopeless appearance on a cursory examination. The crown was gone and almost the whole of the root surface overgrown by gum, which I got rid of as described above.

Examination then showed a large perforation on the distal side of the root extending from the gingival margin to a point about one-third of the root's length above it. Higher up the pulp was found alive and was destroyed; the apex was sealed and carious dentine removed as far as was deemed safe. A cotton dressing firmly packed now simplified matters, and when the parts had settled into place I tapped the apical end of the root and screwed in a German-siver tube. Between the rough outer surface of this tube and the walls of the root I worked as much copper amalgam as I could safely pack, and in this way restored the shape of the root to the gum-edge. When this had hardened, the projecting portion of the tube was cut off and a porcelain-faced crown mounted in the usual way. This crown is still in position and seems likely to remain.

The above cases all seem to me to point in one direction. They are all types, each varying a little but all common enough to most of us and none of them easy to treat. In other situations the merits of copper amalgam may perhaps be justly disputed, but here they are unquestionably good. The plan I advocate, even if by chance it should not give so uniformly good results as it has done during the last six years, is, I feel convinced, far more reliable than the lines of treatment hitherto adopted. Out of a very large number of cases I cannot record one failure. The result in cases formerly deemed most uncertain or even hopeless has indeed been such, that time and a careful trial of this method seem to me to be alone needed to prove that this question of perforation has been practically solved.

No doubt it will be objected that with due precautions perforation should not occur, but inasmuch as no man can see a root lying in the alveolus, measure its depth or gauge the thickness of its walls, he cannot in every case be expected to cope with abnormality with that degree of certainty which such objectors would imply as possible. In treating a difficulty the mental attitude of expectancy is not everything, we also require the physical sense of touch, and

as the conditions imposed by abnormality are often such as to render ordinary precautions of no avail, accidents must happen unless the case be abandoned. Even when an abnormality is successfully diagnosed, the diagnosis does not carry with it perfect results in treatments. This being so, success in the less readily recognizable and quite unrecognizable forms becomes more remote.

If we consider the variations in shape, size, and curvature of certain roots, such as the upper lateral incisors, the upper bicuspids,—particularly the first, often bifid with flattened roots or coalesced canals,—we cannot wonder at an occasional accident even when the dentist is alive to its possible occurrence. Such an accident has, I regret to say, often happened in my hands during the past six years, and in every case the remedy here advocated has succeeded. It is, therefore, with the greatest confidence that I beg to record my experience and to commend its results to my professional confrères.

SOME FEATURES IN BRIDGE-WORK.

BY H. C. REGISTER, M.D.

In Dr. M. L. Rhein's essay upon "Ideal Bridge-Work," read before the First District Dental Society of New York, December, 1893, he states, "At a time when mechanical skill in our laboratories was at its lowest ebb, one of the greatest operative dentists that ever lived, Marshall H. Webb, felt the need for something in the prosthetic line which would approach the ideal of excellence which he attained in his operative work. He took his cue from the work performed by Dr. B. J. Bing, of Paris, and first described in the *Dental Cosmos* of October, 1869, by Dr. H. D. Bennett, of Paris. Dr. Bennett's paper received little attention in this country until 1873, when Dr. Webb began the practice of inserting single artificial teeth into spaces, making anchorage in cavities in the approximal surfaces of the adjoining teeth. His method of work, as is well known, was a vast improvement on the style of that done in Paris.

Reports of isolated specimens of bridge-work are published as early as 1805 by J. B. Gariot, and in 1820 by C. I. Delabarre, and by Dr. S. S. Fitch, of New York, in 1829, and by Dr. W. H. Dwinelle in 1856. To Dr. B. J. Bing, however, is due the credit of reviving this antique method of inserting artificial teeth.

"A paper read by Dr. H. C. Register, entitled 'Grafting Artifi-

cial Crowns in Lieu of Plates,' before the Odontological Society of Pennsylvania, on January 8, 1881, shows that he had for some time been following Webb on this style of work."

This influx of new methods of inserting artificial teeth brought back to our dental laboratories the gold-workers, and private courses for mechanical dentists in plate-, bridge-, and crown-work were a source of considerable revenue to private instructors.

In this manner no one dares to contradict that bridge-work has been a great blessing to the profession. It has been the means of educating the men engaged in the mechanical construction of these devices to a point nearer to perfection in mechanical technique than has ever before existed in dentistry. It has also served as a stimulus to the inventive capacity of dentists, as is readily demonstrated by the vast number of methods of inserting artificial teeth without plates, which are now practised.

In this relation I wish to say a few words in further advancing this really great possibility in prosthetic work. Dr. Webb, in discussing my paper in 1881, believed it possible to attach more than one tooth successfully, although he had never performed that operation himself.

In modern bridge-work there are two essentials,—namely, perfect retaining device upon the root attachments, and perfect cleansing surfaces. These two conditions are essential to the future usefulness of the fixture. Dr. Rhein criticises the so-called self-cleansing spaces generally made, as not only receptacles for *débris*, but as causing constant annoyance to the tongue and interference with speech.

I say with pleasure that I have never placed a bridge with these *cul-de-sacs*, always adhering to the principle of restoring lost anatomical forms.

To these two previous essential conditions I would add a third, applicable to the immediate oral teeth in their artistic relations. I desire to call your attention to the uncertainty of the present method of attaching bridges and crowns, especially those forms where several anchorages are utilized.

Phosphate of zinc is the agent in general use, and where the fixture contains several abutments its application must be made so rapidly that without intelligent assistance there is difficulty in properly adjusting it. It is a matter of considerable concern, after a beautiful piece of mechanical work is ready to be placed in position, whether we succeed or fail in making everything perfectly secure, and carry the bridge to a proper adjustment. To do away

with this apprehension of failure, time should be at the disposal of the operator, and for greater artistic results a *better* crown can be made use of. To get time one attachment should be fixed, and the others following it in rotation, under conditions that the cementing or connecting process should be of such a character and disposition to resist to the greatest extent bacterial invasion.

We might say of phosphate of zinc, with our present knowledge of incipient caries, that it is a preventive of bacterial intrusion, less its comparatively rapid dissolution. This contra-disposition, in connection with its lack of strength when stress is applied, makes it non-dependable for carrying a bridge many years, unless the fixtures be so accurately made as to be self-supporting. In combination, however, with an alloy freshly cut and of good test, thoroughly mixed together, we have almost an ideal preserver of tooth tissue, less its inartistic appearance,—a material into which is worked a matrix that is mutually self-sustaining, both for filling and anchoring bridges or crowns. To apply this retainer in bridge- or crown-work the porcelain face or veneer should be of special form and appropriately made, so as to allow not only of manipulation but of artistic construction as well.

The filling of root-canals with alloy, and the foregoing combination of it and phosphate of zinc, is the method that has proved most successful in my hands. To apply a retainer of this character, the filling must be worked in by manipulation, either on bridge or crown, and the supporting base must be appropriately made to permit the filling-material being placed with confidence, and the artistic relations fully carried out in the work.

I made use of a crown that contained an inverted dovetailed groove placed on the back of the porcelain faces of the cuspids and incisors and the interproximal spaces of the bicuspids and molars.

One of the principal features in crowns of this character is in allowing the root to be filled from the labial or buccal in contradistinction to the palatine side, and of placing the supporting fixture before the porcelain faces are arranged in place, filling each root separately under perfect observation and without hurry, and in case of accidents these crowns are easily duplicated without damage to the fixture.

These teeth between the abutments were placed upon a saddle exactly their own diameter, which rested upon the alveolar ridge, the necks being enclosed in a ferrule for the bicuspids and molars, and in the immediate oral teeth in a half or whole ferrule as best

suited the artistic result to meet the individual case. You will thus notice in the illustration, if at all familiar with the Mason crown, recently placed upon the market, and which opens a great possibility in prosthetic bridge- and crown-work, that they include the same means of attachment so far as the principle is involved.[1]

This method in no way bears upon the ingenious method adopted by Drs. Rhein and Andrews of placing split shells over inverted crowns and fixing them to place with a key.

The principle involved here is in the use of the roots of the teeth, hermetically sealing the same under observation, gaining greater strength in stress, and protecting the underlying tooth from carious influences.

You will notice, if you are at all familiar with the Mason crown, that the face slips off and on the backing to the diameter of about half of the face of the root. Thus in placing the base of either crown or bridge into position, and the porcelain face removed, you have half the root exposed by simply opening up a floored ferrule, and thus exposing the pulp-chambers. Where half ferrules are used the same result, of course, is gained.

The pin for anchorage into the pulp-chamber can be soldered directly to the backing, or a split post, with the ends bent in opposite directions resting upon the ferrule, packed to position through this opening.

Where amalgam is used slight oiling of the gold should precede the adaptation to prevent its amalgamation. Everything being ready, the parts dried, a creamy compound is made of phosphate of zinc alone, or equal parts of phosphate of zinc and alloy thoroughly rubbed together under a heavy spatula, and the inner edges of the ferrule anointed and pressed to place.

If preferable, in this part of the work phosphate of zinc can be used alone; this is to fix the bridge or crown to position.

After drying that part of the retainer and with an excavator removing from the canal through the opening into root all excess, and desiccating by means of compressed air, repeat the combination mixture, except to make the second and other mixings stiffer in the phosphate of zinc and drier in the alloy. After thoroughly mixing with the spatula manipulate with the fingers into a putty-like consistence, rolling it in the fingers to about the size of the opening

---

[1] The principle involved, and the type of crown employed in the Mason adjustable crown, have been used by Dr. Rhein for several years. He states that the device was suggested to him by Dr. Van Woert.—(H. W. B.)

in the canal. If the retaining post is attached directly to the bridge, pass it in piece by piece till the parts are thoroughly packed.

If using a split post, after filling the upper portion of the canal, press it home to position, and fill the same as if it were permanently attached, finishing the last layers with alloy alone. Where a half ferrule is made, this is carried to the edge of the root under the gum festoon. The tooth crown, which has previously been properly adapted, is now connected with the base either with phosphate of zinc or chloro-percha.

Where it is desirable to resist the greatest stress I recommend the use of alloy alone, packed in the same way as the preceding mixture.

In spaces between the abutments, where resorption has followed the extraction of teeth, there is characteristic tooth and gum contact which gives an artificial appearance to the facial expression.

To overcome this artificial appearance it is necessary to reproduce the gum festoon. The reforming of this on the faces of the teeth consists in taking the mucous and submucous tissue, with some fibre, from the palatial or lingual portion of the jaws in the form of flaps cut in festoons as wide as the teeth where they join at the interproximal spaces, and stretching it over the faces of the teeth, allowing the flaps to be twice the length required, proportionately large to allow for shrinkage.

The granulating process from where these flaps are taken may be packed with iodoform gauze or cleansed with an antiseptic wash. The cutting can be done with very little pain with cocaine or eucaine hypodermically injected; and where specially desired by the use of the Mason crown, one or more operations can be done at a sitting.

This is the method which I have employed in producing the plastic reformation of gum festoon. But there are conditions where one flap to each space can be made and laid over the faces of the teeth and a stitch made between each interproximal space, drawing it tightly around the necks of the teeth and trimming away excessive gum tissue in the reforming of the gum festoon.

The base of the bridge being in position, the crown faces are first placed on the root abutments. I prefer to make these attachments with the phosphate of zinc, which will remain firm for several years, and can be readjusted easily without disturbing the other part of the fixture. The flaps, after being cut and dissected away from the periosteum, are caught by ligatures passed under them and

drawn forward, thus suspending all hemorrhage; as many being done at one sitting as is advisable under existing conditions. After which the crowns are flowed over on both contacting surfaces with phosphate of zinc and pressed to place, pinching into the interproximal spaces, followed by thorough drying, when the ligatures can be removed, allowing them to fall over the faces of the

FIG. 1.

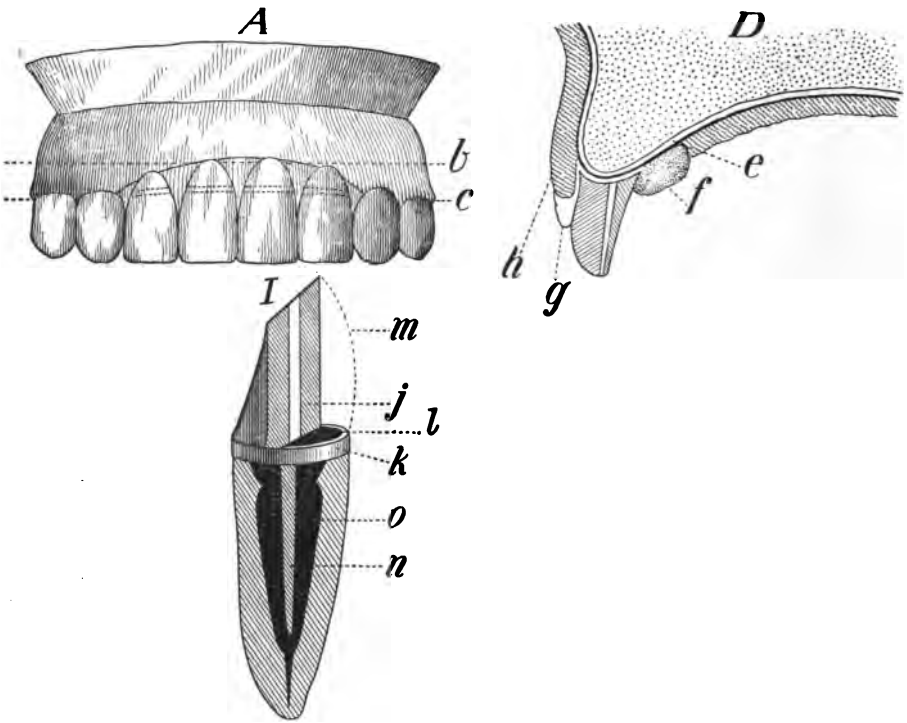

A, model showing great absorption of alveolus between cuspid roots and nearly two-eighths of new gum festoon reproduced: *b*, original line; *c*, new line.

D, showing how flaps were taken from palatine portion and pushed forward to labial surfaces: *e*, muco-periosteum; *f*, iodoform or nosophene gauze, forced in and tied; *g*, extra long flap to allow for absorption; *h*, new gum festoon.

I, Mason crown enlarged for showing method of attaching to root with alloy: *j*, Mason backing; *k*, ferrule,—can be made a whole or half ring as required; *l*, opening to canal on labial side, through which filling is packed; *m*, Mason crown, pushed to place, covering the filling space; *n*, pin in root; *o*, filling around pin.

teeth, and the palatine portion packed with iodoform gauze. This is not essential, however, as an antiseptic wash answers every purpose.

There are conditions, however, when iodoform gauze can be

packed on the palatine portion (under the bridge) to advantage, in giving a better expression to the gum festoon during granulation by causing it to bulge.

In a case performed by myself last winter, a most gratifying result was secured for the four incisors attached to the cuspid roots, where a crescent-shaped arch was caused by recession, the centrals being fully twice the length of the cuspids. This discrepancy, which was very unsightly on account of the incisors having to be so much longer, was wholly overcome by using long flaps over the centrals, and shorter ones over the laterals, reproducing the gum on a line and festoon between the abutments. This is illustrated in Fig. 1.

I saw this patient several months after operating, and the gum presented nearly a perfect line between the cuspids, and the granulation which had followed the filling in of the spaces from where the flaps were taken presented a perfectly healthy and normal appearance. A singular and gratifying result from this operation, in connection with the plastic work, was a perfect tightening of the roots, which before presented considerable luxation.

With that class of patients showing the gum-line of tooth contact this plastic operation of gum-formation opens up a new line of possibilities in giving most pleasing results, which I feel sure will find some commendation in artistic bridge-work.

DISCUSSION.

The President.—These papers are now open for discussion.

Question.—Why should paraffin not be used for this purpose? Certainly it is, theoretically, an applicable material.

Dr. Inglis.—I have used paraffin for perforation near the apex of the root. It has the virtue of easy removal.

One difficulty of treating these cases of perforation near the apex is the sterilization and filling of that portion of the canal which lies beyond. There is always a doubt as to the condition of this apical portion of the canal. The first thing to do with a perforation is to diagnose it. The cases that I have seen have occurred in consequence of the lateral cutting of reamers which were not held in the axis of the tooth. A fine probe passed towards the apex causes pain and immediate hemorrhage. I have pursued the following method: A gutta-percha cone is introduced, and its point cut off, until no sensation is produced, when it is placed in the canal. This is coated with thick chloro-percha, and slowly but fully introduced; however, it had better be too short than too long.

For the large lateral perforations I use a plaque of gutta-percha. In one case of perforation with an external fistula overlying it, I pressed back the soft tissue, exposing the perforation through the gum; then placing a gutta-percha cone in the canal, I treated the perforation as a cavity,—filled it from the exterior with facing amalgam. The wound healed, and the tooth is now doing good service.

Dr. Darby.—My son had a case closely analogous in its relations to perforation of the root. A boy, aged eleven years, fell and drove his central incisors out of position. The teeth were replaced in position and held firmly until healing occurred. The pulps of the teeth which had been devitalized by the accident were removed, and it was found that the foramina were of immature size. I suggested that the canals be reamed to the size of the foramen; then, by measuring the exact distance from the floor of the pulp-chamber to the apex of the root, a gold wire was placed in the latter, and a shoulder made by cutting away the wire to the diameter of the reamer employed; the thinned portion was then cut off and the end rounded until it exactly equalled in length the length of the canal, the shoulder engaging and resting upon the floor of the pulp-chamber. The wire, dipped in thin chloro-percha, was placed in position and served as the canal filling.

I want to sound a warning as to the use of copper amalgam. Placed in the crowns of pulpless teeth, it will certainly discolor the crowns if no impermeable layer be interposed between the filling and the dentinal walls.

Dr. Register.—It does not discolor roots in which it is placed.

Dr. Darby.—It will be discolored whenever placed in such situations as the decomposition of albuminous matter is found; wherever hydrogen sulphide is formed copper amalgam will discolor, and it very frequently is formed in pulpless teeth by the decomposition of the organic contents of the dentinal tubuli.

Dr. Truman.—There is one phase of this matter which is not receiving the attention it should in our discussion, and that is the condition of the parts as regards sepsis. The older the perforation the greater is the difficulty of producing sterilization, and until perfect antisepsis is attained, we must consider the danger of degeneration of the vascular tissues about the parts. The difficulty of successfully treating lateral perforations is greatly increased if the parts are permitted to become or remain in a septic condition.

Dr. Register.—The best treatment for perforation is the preventive treatment. If in reaming canals we perform the operation

very carefully, it will be found that, as the instrument approaches or touches the cementum, the patient will give evidence of pain; if the patient be previously directed to state when sensation occurs, perforations should never occur. When I find that the instrument (the reamer) has invaded the cementum, I sterilize the canal thoroughly, and am careful to exercise no pressure in placing the root-filling.

Those cases of perforation near the apex which I have encountered I have treated after one method. Packing in the canal, and against the pericementum at the perforation, a small quantity of salol, and over this a cone of zinc phosphate is placed. Of course, the salol disappears, as it always does, after a period when used as a canal filling; but I believe that it performs office as an unirritating antiseptic while it lasts.

Dr. Guilford.—Accidents of perforation are always to be well guarded against. In those cases involving the floor of the pulp-chamber of molars, I cover them with a piece of moistened court-plaster and fill over it.

When the perforation is near the root-apex, I think it best to amputate the portion of root above the perforation. The canal is filled with gutta-percha, an opening is made through the alveolar wall above the point of perforation, and the apex of the root is cut off, and smoothed by means of fissure burs. The piece is dislodged by means of an elevator, and the wound cavity packed with iodoform gauze.

Dr. Roberts.—I have used tin-foil instead of court-plaster for this purpose, after sterilizing the parts. Stiff zinc phosphate is then to be packed over the tin-foil.

Adjourned.

A REGULAR meeting of the Academy of Stomatology of Philadelphia was held November 23, 1897, Dr. Edwin T. Darby in the chair.

A paper on "Arsenical Necrosis" was read by Dr. Otto E. Inglis.

ARSENICAL NECROSIS.

BY OTTO E. INGLIS, D.D.S., PHILADELPHIA.

Very little has been written in text-books for students upon the subject of the escape of arsenic trioxide from a cavity of decay upon the gum. A general warning to avoid such escape is alone given. Specific directions as to the treatment of any condition that may arise from carelessness in this direction are searched for in vain. Garretson recommends "repeated syringings, and gives the information that the sequestrum which is formed is seldom considerable." The writer has had the good fortune to be placed where a considerable number of such cases fall into his hands, and while he can gladly agree with Garretson in that the sequestrum is seldom considerable, he feels that the information is vague and not sufficient unto the need of the anxious young practitioner or student who has such a case on hand, as the result of his lack of care or ignorance. Accidents will happen, and we should be provided with the antidote,—viz., a knowledge of how to proceed to neutralize or cure their effects.

First, let us consider how arsenic acts upon gum tissue. To this end the scientific experiments of Dr. J. H. McQuillen are worthy of attention. He took a frog, and to the web of its foot applied a grain of arsenic. The effect was noted by the use of the microscope. Dr. McQuillen says,[1] "For the first half-hour or so no apparent change was observable in the circulation: in a short time after this, however, the vessels sensibly increased in size and the circulation in rapidity of movement. The oval-shaped red corpuscles of the frog could be seen not only rushing through the vessels much more rapidly, but also in greater numbers than in the normal circulation. This continued for some time, and then the rapid motion of the circulation gradually decreased, the blood-corpuscles moving along slower and slower and apparently clinging to the walls of the vessels as if unwilling to leave them, and when doing

[1] Dental Cosmos, vol. iii. p. 581.

so only yielding on account of the *vis a tergo.* The circulation went on decreasing until eventually complete stagnation supervened. This condition was not confined to the immediate vicinity of the spot on which arsenous acid was placed, but extended over the entire web. . . . The first frog died promptly, and arsenic was found in the muscular tissue of its heart. A second frog, which was treated in precisely the same manner, exhibited similar local inflammatory effects, but the inflamed part sloughed out, leaving an aperture in the web. It lived over a week in the apparent enjoyment of health, and then, through the carelessness of a domestic, it escaped." Dr. McQuillen inferred that arsenic could be classed as an irritant poison. We may infer from these experiments that arsenic is absorbed into the general circulation or prevented from so doing according to the degree of inflammation existing between it and the heart. We have further evidence of this in the application of arsenic for the removal of tumors. If a small quantity be applied systemic poisoning may take place, but when a large quantity is used, stasis is brought about so rapidly between the arsenic and the general circulation that absorption ceases because there is no circulation to superintend absorption. Bearing upon the consideration of this subject is the fact that, according to the authorities, the injection of arsenic produces enteritis. There seems to be no direct evidence that arsenic is a chemical irritant, escharing after the manner of phenol, which combines directly with the albumen of the tissues, although the statement has been made that arsenite of albumen is formed. In an attempt to determine this point the following experiments were performed. With a teaspoonful of fresh egg albumen, ten grains of arsenic trioxide were thoroughly triturated in a mortar at a temperature of 98° F. No coagulation took place at any time during a week or more, while the arsenic gradually settled to the bottom of the mortar, leaving clear albumen supernatant. A high temperature would undoubtedly have coagulated the albumen. A second experiment was made, the arsenic being ground into the albumen and then three times the volume of water added and the mixture again triturated. A magma composed of arsenic and albumen settled to the bottom of the mortar. The question now being whether the coagulum was due to the arsenic or to the water, a third experiment was performed. This consisted in taking one part egg albumen and three parts water and triturating. A flocculent coagulum was at once formed which, lacking the weight of the arsenic, did not settle.

We can only conclude that the coagulum formed by the water

held the arsenic suspended in its meshes. The experiments are offered for what they are worth So far as seen arsenic must be classed with irritants which act through the inflammation they are capable of producing.

Biddle[1] states, upon the authority of Scolosuboff, that in arsenical poisoning, if in fresh muscle one part of arsenic be found, the proportion in liver is ten and eight-tenths parts, brain, thirty-six and five-tenths parts, and in the spinal cord thirty-seven and three-tenths parts.

This would seem to show an enormous selective affinity of the drug for nervous tissue. May we not justly infer that this selective affinity accounts for the hyperæmia of parts distant from the seat of application (as in the web of the frog's foot). In other words, that the drug after absorption exhibits an affinity for the vasomotor system producing paralysis of the vasoconstrictor nerves. This being permanent, the capillaries are unable to contract and complete stasis results.

When arsenic escapes upon a gum, the first effect is probably the irritation of the vasomotor nerves and their subsequent paralyzation. This causes atony of the vessels and in consequence stagnation of blood ensues as may be seen by the turgid condition of the gum festoon.

Later, this festoon becomes of a dirty yellow color, which signifies that it is gangrenous. The extent and direction of the necrosis depend upon the amount of arsenic which has leaked upon the gum. As the amount is generally small, systemic poisoning cannot usually result, although it is probable that some arsenic is absorbed into the general circulation. When leakage of arsenic takes place from a tooth-cavity, different parts are attacked, according to whether the arsenic is confined against the gum septum or allowed to diffuse itself.

In the writer's experience, the mixture of arsenic and creosote, as furnished in the ordinary "nerve paste," has produced more serious results than the pastes in which the arsenic is distended with morphine or other admixture. This is another evidence of the fact that effect is in proportion to the quantity of arsenic allowed to escape.

The following may be held as expressing the amount of damage done:

1. Necrosis of gum septum.

---

[1] Materia Medica and Therapeutics, p. 472.

2. Necrosis of gum border encircling one or more teeth.

3. Limited necrosis of bone directly underlying these parts.

4. Extension of the area of necrosis along the pericementum, with loosening and bloodless loss of the tooth.

5. Necrosis beginning at some high portion of the alveolus, as when arsenic is applied through a perforation.

6. Necrosis beginning at the apical foramen owing to the forcing through of arsenic.

7. Necrosis of tissues of the cheek or lip.

Let us consider these in their proper order.

NECROSIS OF GUM SEPTUM.

This limited amount of necrosis could of course only occur as the result of leakage of a very small amount of arsenic, or as limited by prompt surgical interference. It will be evidenced in its first stage by a turgid condition of the gum between the teeth. This will be succeeded by a yellow slough. The part should be thoroughly syringed to remove any arsenic present. The tooth-cavity may be opened, the pulp removed, and the canals filled. The slough should then be curetted away with a large spoon excavator or small lancet. Antiseptic gauze is then to be placed against the gum between the teeth, and the patient is to be directed to syringe the part with three per cent. pyrozone or one to two hundred solution of potassium permanganate in water. Regeneration may be expected.

NECROSIS OF GUM BORDER ENCIRCLING ONE OR MORE TEETH.

This condition occurs as the result of leakage of a considerable amount of paste, the same not being confined to the dental interspace. It is apt to occur when very fluid preparations have been used in undue quantity. It is peculiar to fluids to follow the festoon of the gum. This may be noted when, during excavating, the gum has been made to bleed. The blood will trickle backward, following the line of the festoons. The same will also be noted with carbolic acid; if applied in excess, the festoons will be eschared. As carbolic acid is a common menstruum for arsenical pastes, it is not necessary to say more on this point.

This would seem to be an especially dangerous manner for the arsenic to distribute itself, as indeed it is, especially in the inferior jaw, where gravitation favors its retention within the gum festoon. The pericementum having its attachment at the festoon is readily attacked and the tooth lost. In the superior jaw the danger is

seemingly not so great. At any rate the same disastrous results have not been observed. The dead tissue should be curetted away, the part kept aseptic, and regeneration will usually take place.

NECROSIS OF BONE DIRECTLY UNDERLYING THE SOFT PARTS.

When a limited amount of leakage has caused necrosis and the same is neglected, a small portion of the alveolar process becomes necrosed and forms a sequestrum. This may persist in its position for many months after separation, owing to the peculiar retentive shape of the bone. A certain amount of liquefaction into pus may result, but, as a rule, in from three to six weeks operative procedures are necessary. The sequestrum should be divided at its middle portion and removed in two pieces.

This death of bone is due probably to the loss of its source of nutrition,—viz., the periosteum, and possibly also to the entrance of organisms to the part. These produce a septic gangrenous condition against which the vital tissues react. The result is demarcation of the bone and its sequestration by a line of pus.

When the bone has been lost, it is found that the adjoining teeth are denuded, their pericementum to an extent nearly corresponding to the size of the sequestrum. Some regeneration will take place, but there will also be more or less deformity resulting from the loss of bone tissue. It has been the experience that when a quantity of arsenic has been used larger than will produce a limited death of bone the pericementum is so affected that the loss of at least one tooth results. When the process has been affected, as will be indicated by its insensitivity at points underlying sloughing gum tissue, it should be gently scraped or burred away until sensitive tissue is reached. The part should be frequently syringed with pyrozone and the result awaited. If nothing else be accomplished by this treatment, the arsenic at least will be removed and the extent of necrosis, in all probability, limited. The following is a description of the case which resulted in the largest sequestrum of process without loss of the tooth that the writer has seen. The application was made to a mesio-occlusal cavity of a molar in January, 1897. In about three weeks a sequestrum of the septum about one-third inch deep was taken away. The lingual and buccal margins of the process were affected about alike.

The case was seen again, November 1, 1897. The gum had receded, exposing the cementum from the middle of the cervix on the distal root to a point about one-quarter inch below the cervix on the mesial root.

The tooth was somewhat looser than normal, due probably to chronic peridental irritation with food fermentation, calculus, etc., as cause. The gum edge was somewhat thickened.

Dr. J. H. McQuillen[1] instances a case in which by syringing with tepid water and applications of creosote and iodine he succeeded in saving two bicuspids, but was compelled to remove a considerable portion of the process, in consequence of which there was considerable disfigurement.

EXTENSION OF THE AREA OF NECROSIS ALONG THE PERICEMENTUM, WITH LOOSENING AND BLOODLESS LOSS OF THE TOOTH.

This may result from confinement of arsenic against the septum or from its distribution around the festoon. These are the cases in which accrue results causing much chagrin to the operator. Nothing can be more disastrous to one's reputation than to bring about a deformity where a simple remedial measure was intended. When the arsenic begins its action upon the pericementum at the gum line, whether between the teeth or at the festoon, and the case is neglected for a few days, it may rapidly destroy the membrane. The tooth becomes loose and sore and may in some cases be extracted with the fingers, or even in the attempt to remove a temporary filling.

The surrounding gum tissue is not always as much affected as one would expect. After the tooth is removed the alveolus is found bare, bloodless, and septic. There is no doubt of its septic condition, as the odor of the tooth will resemble that of a tooth extracted for phagedenic pericementitis. The fermentation of stagnant saliva and serum will account for this. Were the case neglected at this point, it is probable that the alveolar cortex or process enveloping the tooth will be thrown off. A specimen is presented, taken from the mouth of a boy of fourteen years. Arsenic was applied to a distal cavity in a superior first bicuspid. The gum septum necrosed. Free curetting was indulged in, but the pericementum had been so profoundly affected that the tooth loosened and was extracted. Later the envelope of process was taken away.

Later, Dr. J. Foster Flagg[2] mentions a case in which a second superior bicuspid and first molar were lost, together with all the intervening process, as the result of a persistent application of arsenic to a distal cavity in the bicuspid. Leakage occurred.

---

[1] Dental Cosmos, vol. xiii. p. 394. [2] Ibid., vol. x. p. 635.

Another phase of the condition was presented in the case of a young girl fifteen years of age. The application was made to a left inferior second molar. The pericementum necrosed, and the tooth was extracted without the loss of a single drop of blood. The apices of the alveoli were drilled away to healthy bone, in order to avoid any possibility of extension of the necrosis in the direction of the inferior dental canal. The writer then decided to experiment upon the case, and directed the patient to make application of three per cent. pyrozone upon cotton three times daily. The case was seen twice a week for two months, after which the patient was discharged cured.

There seemed to be a molecular death of the cortical bone upon the exposed side, which the pyrozone removed. Upon the side of the cancellated bone vitality was maintained. The cortex became thinner and thinner, until granulations began to spring through the walls of the alveolus. No doubt there was some absorptive action upon the bone by the healthy tissues. Such action is not uncommon under other circumstances, as may be seen upon the roots of some chronically abscessed teeth, or upon planted teeth.

The foregoing treatment was merely experimental. The removal of the cortical bone by surgical means (*i.e.*, with a large bur in the engine) and the induction of tissue regeneration is preferable.

NECROSIS BEGINNING AT SOME HIGH PORTION OF THE ALVEOLUS, AS WHEN ARSENIC IS APPLIED THROUGH A PERFORATION.

The writer has seen several cases of this sort. When so applied, the necrosis extends in all directions, following the pericementum and attacking the bone. If promptly discovered and treated by removal of the dead portion, some hope may be entertained of retaining the tooth, but only at the expense of loss of tissue. If neglected, not only one but two teeth may be lost, this being dependent upon the quantity of arsenic applied.

Perforation by drilling is not always easy to differentiate from a partially devitalized pulp. In doubtful cases it is better to avoid the use of arsenic. The following is a description of the only case occurring in the writer's private practice:

One busy day a lady requested treatment of a left lower second bicuspid, which had been in the hands of an incompetent practitioner. The patient could give no history, except that much pain had been inflicted. Examination revealed what seemed to be a complete exposure of the pulp, but which results proved to be hypertrophied gum. The usual application was made, and the

patient dismissed for a few days. Upon her return a necrosed condition of the septum between the second bicuspid and first molar was discovered. The bicuspid was opened and found to be perforated upon the distal face of the root. The opening was a line in diameter, and made evidently with the intention of opening the root-canal. The case was cured by extraction of the bicuspid and curetting the parts. The specimen is exhibited here, and it will be plain that any one would be warranted in following the treatment of the supposed pulp as was done.

In this connection it is well to call attention to the liability to this accident in cases of gum proliferation through a carious perforation of the root. The practice of establishing the diagnosis before attempting to apply arsenic is evidently correct.

NECROSIS BEGINNING AT THE APICAL FORAMEN.

There is no doubt in the writer's mind that many cases of chronic peridental irritation have occurred as the result of careless broaching. In all cases where paste has been applied, especially when placed in the root, the arsenic should be removed by alternate broaching and syringing. The writer has never been able to positively connect arsenic with apical irritation, but has suspected its occurrence after the manner indicated in a number of cases.

A unique case has been reported by a professional friend. He made an application to a pulp, but, finding it only partially devitalized thereby, he applied cocaine by cataphoresis without removing the traces of arsenical paste from the tooth.

A slough of three lines' diameter appeared over the apex, but was gradually thrown off by tissue regeneration beneath. Whether this result was due to cataphoric action or to mechanical conveyance of the arsenic to the apical space is not clear. This history may cause us to infer that there exists toleration of a certain amount of aseptic slough by the tissues of the apical space. We may bear in mind to what extent the escharotic action of zinc chloride and carbolic acid are tolerated by these parts.

NECROSIS OF THE TISSUES OF THE CHEEK.

This simulates quite closely the ordinary aphthous ulcer, is usually slight, and requires little attention. If extensive, however it should be treated upon the principle of exciting an inflammation to check the absorption of the drug. Free cauterization with argentic nitrate succeeded admirably in a case of deep penetration of arsenic into the tissues of the buccinator muscle at a point near

the lower third molar. The treatment of arsenical necrosis of any magnitude with ferric hydrate has not resulted happily for the writer; perhaps the fault may lie in the difficulty of its maintenance in position. It is difficult to understand, however, why it should be expected to more than remove the unabsorbed arsenic from a part, inasmuch as dead tissue lies between it and the advancing arsenic.

It would be an omission, having stated the ill effects of arsenic when allowed to escape upon the gum, not to mention some means whereby leakage may be prevented. The quantity of paste used should be as minute as possible, and should be carefully sealed in the cavity. In accessible places, where the rubber dam can be applied, and especially in the lower teeth, the application may be made upon the under side of a small piece of letter-paper, and thin zinc phosphate flowed over it. The method is necessarily of limited application, owing to the unmanageable nature of the zinc phosphate. Temporary stopping is a material much lauded for this purpose. It should never be used in cavities the margins of which go beneath the gum, unless the rubber dam can be applied. As it requires a certain amount of pressure, which, if exerted upon the arsenic, will either insure its escape from the cavity or cause compression of the pulp, a cap of metal should be placed over the application. Pressure may then be exerted at will. Gutta-percha is a material too difficult of proper use to be relied upon in preference to temporary stopping.

A method employed by the writer is to first build in the cervical portion of the covering; next to make the application and cover it with a pellet of dry cotton; then to build in the remainder of the covering. Where cavity margins are in dangerous proximity to the gum, or where mechanical retention of the covering filling is but slight, and where the rubber dam cannot be applied, nothing can be better than an amalgam made from an alloy of forty parts silver, fifty-five parts tin, and five parts zinc, and known as "Flagg's facing." It absolutely does not leak, but probably expands, causes no pressure in its insertion, does not discolor within a considerable length of time, and is easily removed with an excavator. When desired, it may be relied upon for any reasonable period to maintain its position, even under the stress of mastication.

To illustrate: A right lower third molar had a large buccal cavity with the cervical margin under the gum, which also slightly overlapped it. The exposure of the pulp was complete, and business necessity rendered an immediate application desirable.

Though this represents, perhaps, an extreme case, yet the writer's experience is that in the clinical service frequently, and in private practice not so very seldom, cases of quite as puzzling a nature have to be dealt with. Facing amalgam, handled more or less in the manner about to be related, may be relied upon.

The cavity was first cleansed, and undercuts made along the mesial and distal walls. Disinfection with three per cent. hydrogen dioxide followed. A pellet of cotton was laid upon the pulp, and a small portion of soft amalgam was inserted back of the flap of gum and pressed outward, carrying the gum with it. The cavity was then filled with the amalgam. An excavator was now used to cut down through the buccal aspect of the filling upon the cotton, which was then removed. Arsenic upon cotton was placed upon the pulp, and a small portion of amalgam used to seal the tap. When it is desired to remove the covering, a dentated bur is passed into the tap, and the filling easily divided in two, when the halves may be crushed together. Ordinarily a small cervical portion may be left for the support of the clamp during treatment of the case. When this is completed it should, of course, be replaced by other material.

When the exposure is found upon a surface which is inaccessible by any ordinary method, as when a cervical cavity exists upon a distal face of a molar, what is known as a "pocket" should be made. This is a drill-pit made in the direction of the horn of the pulp, and preferably, for pathological reasons, towards one that is not exposed. Sometimes the pulp may be very closely approached. Arsenical paste is then sealed in the pocket, while soothing medicaments are to be placed in the cavity of decay. Of course, cataphoresis may be considered in any of these conditions, but with that we are not at present dealing.

Within the past few days, and since this article was written, the writer was consulted by a gentleman from Demarara, who desired some fillings made.

In the course of the operations mention was made of the excellent quality of his teeth, and sympathy expressed for the loss of every tooth back of the first bicuspid upon the right side of the lower jaw. He said he had with his fingers removed them all at once, together with the bone surrounding them, as the result of an application of "something to quiet an aching tooth." There was a very flat and greatly depressed condition of the ridge where the teeth had been lost, which seemed to bear out his statement. If there be truth in his story, we have no reason to doubt that arsenic was the medicament used, probably in considerable quantity. We

may also learn to what extent necrosis may result without loss of a portion of the maxilla proper. The writer does not vouch for the case, but gives the facts as they were related to him. It may serve, at any rate, as a warning, and at the same time as an encouragement should an accident occur.

DISCUSSION.

Dr. S. H. Guilford.—The subject which has been chosen by the essayist is an interesting one. We have all of us had more or less experience with the escape of arsenic upon the gum, though such an accident is not likely to occur where reasonable care has been observed. The fault in such cases may lie in the contributory negligence of the patient. I recollect one case in my early practice where I applied arsenic to two bicuspids in the superior jaw of a young lady, giving instructions to her to carefully maintain in position the coverings of cotton and sandarach varnish which it was then the custom to use. She was to return in a day or two, but I did not see her for a month. Upon examination I found considerable necrosis, and a portion of the septum had to be removed. Our greatest safeguard undoubtedly lies in the careful sealing of the application in the cavity, though I fail to see why zinc phosphate is not as generally applicable for this purpose as facing amalgam.

Dr. James Truman.—I was pleased with the essay, and especially that portion of it which dealt with the theory of the action of arsenic upon the tissues. There has been but comparatively little attention paid to the phase of the subject selected by the essayist, and any one who has been in a position to observe knows the carelessness with which frequently students handle this drug. I cannot agree with the essayist in regard to the use of ferric hydrate. In those cases of necrosis in which I have been consulted by students I have generally been able to control the action of the arsenic with dialyzed iron, which is equally a chemical antidote for arsenic and is a more available drug.

If left to itself arsenic acts upon the gum-tissue, penetrating more and more deeply until it becomes inert; then that portion which has been chemically destroyed is thrown off. It is true that even with the use of dialyzed iron some tissue will be sequestered, but I believe it to be only that which is destroyed before the case is taken in hand, and that the action would have been greater had not the antidote been used.

Dr. H. C. Register.—The essayist has certainly brought out some

nice points in regard to the action of arsenic. A very few cases have occurred in my practice, and in each instance the action upon the gum-tissues has been slight and seemingly controlled by the application of the ordinary antidotes. In applications to the pulp, I have found the action always happier when the hyperæmia of the pulp is first relieved by depletion. Carbolic acid has not seemed to act so well as a menstruum as other and milder medicaments, such as the oil of cinnamon.

According to the experiments of E. Riegal, arsenic does not act upon mucous membranes unless the cuticle is in some way broken or injured. When this has occurred, however, the action is only limited by the power which the given quantity of arsenic has of combining with the tissue. It may be that the use of carbolic acid as a menstruum may effect that injury which is necessary for the action of the arsenic upon the gums.

I have great faith in the ferric hydrate as an antidote, but it should be used in quantity sufficient; it being calculated that twelve times the amount of the arsenic is the quantity necessary to effect neutralization.

Dr. G. C. Chance.—A personal experience has led me to believe that there is a great evil practised by druggists in dispensing a preparation of arsenic for relief of toothache. One evening, when suffering from pulpitis, I asked of a nearby druggist a preparation of oil of cloves and morphine acetate. He assured me that he had a preparation containing only those ingredients. Reluctantly I accepted his cure, with the result of increased pain. Upon examination next day by a professional friend necrosis of the gum septum was found. Inquiry elicited the fact that incorporated with the mixture was also a percentage of arsenic. As not only this particular druggist, but several others of whom I have inquired, have wonderful faith in this preparation, I think that we should caution their profession against the evil results likely to come to the patient from the use of arsenic in so careless a manner.

Dr. H. B. Hickman.—In November, 1896, a lady came to my office with the inferior left first bicuspid abscessed with fistula of several years' persistence. After removing an amalgam filling and extirpating a dead pulp, I treated in the usual manner with carbolic acid, creosote, etc., but could not close the fistula for more than a few days at a time. After exhausting the list of medicinal agents I filled the pulp-canal with aristo-paraffin, forcing it through the fistula until it appeared upon the gum. On the point of the wax I found a small particle of amalgam, and thought I had discovered

the cause of the trouble. An unusual amount of aristo-paraffin was required.

As the fistula continued to recur, I dissected the gum back and with a large bur cut out all the necrosed bone lining a pus-cavity of considerable size, into which my paraffin root filling had probably been forced in the first instance. I then smoothed the root. After flooding the bone-cavity with a disinfectant, I dried it as well as possible, filled the root with aristo-paraffin, and drew the lips of the wound together with a stitch. Up to the present time the fistula has not returned. The second bicuspid was lost ten years ago as the result of an arsenical application carelessly secured. Is it possible that the necrosis over the first bicuspid root could have been the result of arsenical action?

Dr. M. J. Schomberg.—There is considerable room for scientific thought relative to manifestations of the local action of arsenic on living tissues. In explanation of the manner in which these manifestations, namely, ulceration, death, and necrosis, are brought about, a few facts should, to my mind, be taken into consideration. In the first place, we are all familiar with the preservative property of arsenic, it being used in the preparation of cadavers for preservation. Then again we know of its marked power of penetration. In a few cases where arsenic was taken with suicidal intent into the alimentary canal, post-mortem examination revealed by the test for arsenic that it was present in the brain. Now, granting that the chemical properties of dead tissue which has not undergone putrefaction is precisely the same as living tissue with the exception of vital force, and noting that in the former it preserves and in the latter it destroys, we must come to the same conclusion as the essayist,—viz., the cause of necrosis of the tissue is the stasis within the blood-vessels. Again, this explains why the necrosis is localized, congestion preventing the absorption and distribution of this irritant poison. However, when portions of sequestra are thrown off the arsenic resident in the mass may attack adjacent parts.

The President.—We will ask Dr. Inglis to kindly close the discussion.

Dr. Inglis.—The first speaker mentioned the relative merits of amalgam and zinc phosphate as coverings for arsenical applications. My own experience with zinc phosphate is that in proportion to the difficulty of placing the covering is it an unmanageable material. If used in a very soft condition it adheres readily to everything except the desired parts, and if mixed stiff it requires

an undue amount of pressure. Where the rubber dam can be used, and in situations in which it can be flowed over the application, it is admirable. I was glad Dr. Truman mentioned the carelessness of students in this matter of arsenical applications. I recall one case in which I was consulted by a young graduate who had applied to the exposure in a buccal cavity of a lower molar a quantity of the S. S. White paste equal to twice the size of an ordinary pinhead. This he covered by squeezing temporary stopping directly down upon the application. This was gross carelessness and ignorance, yet this gentleman was a good operator from the manipulative point of view.

It is very difficult to estimate the value of dialyzed iron in cases of arsenical necrosis, inasmuch as the quantity of arsenic escaped varies so greatly, also the time elapsing between the inception of the trouble and the presentation of the patient is a factor which renders it doubtful if dialyzed iron is of more value than mere mechanical removal of the arsenic. There seems to be no case in which the arsenic is not self-limited in action. These two factors—quantity and persistence of application—seem to control the extent of the necrosis.

A REGULAR meeting of the Academy of Stomatology was held on Tuesday evening, December 28, 1897, at 1731 Chestnut Street, with the President, Professor Edwin T. Darby, in the chair.

A paper on "Syphilitic Affections of the Mouth" was read by Dr. H. H. Burchard.

SYPHILITIC AFFECTIONS OF THE MOUTH.[1]

BY HENRY H. BURCHARD, M.D., D.D.S.

The recognition of syphilitic lesions about the mouth is of vital importance to the dental operator, first, because by their recognition he may take steps to prevent the carriage of infection to innocent patients, and, secondly, that he may avoid inoculation of himself by the poison.

Syphilis is associated in the minds of many with the lower classes of persons who are confirmed debauchees; while it is undoubtedly true that its prevalence is most marked in this class of persons, it appears, and with horrible frequence, in individuals who would be little suspected of having such infection. The operator is to be guided in his opinions and precautions in this matter not by the social status of the patient but by the nature of the morbid conditions existing.

The disease syphilis is usually divided into three stages: primary, secondary, and tertiary. To these might be added a fourth stage, —viz., in patients who have been discharged as cured. Mild manifestations of disorders, particularly of the skin and mucous membrane, make their appearance from time to time, and disappear promptly upon the administration of iodides.

The first stage of syphilis, primary syphilis, consists in the formation of the primary sore or chancre and the involvement of the nearest lymphatic glands.

Secondary syphilis appears after the first, and is attended by fever, inflammations of the skin with eruptions, inflammation and superficial ulcerations of mucous structures.

In tertiary syphilis destructive inflammation of the skin and mucous membranes and of connective tissues occur, together with the formation of specific tumors, gummata. Some difference of

---

[1] Excerpt from chapter on Infections in Dr. Burchard's new text-book of "Dental Pathology and Therapeutics." Lea Brothers & Co., 1898. (In press.)

opinion exists among syphilographers as to the relative infective power of the secretions from the several lesions of syphilis; all are agreed, however, that the secretions from the secondary lesions observed in and about the mouth are highly infective. It is the part of prudence to regard lesions of all stages as infective.

All three stages of syphilis may be seen in the human mouth. It is to be remembered that if the mucous membrane of the mouth be infected from a mucous patch, which is a secondary lesion, the acquired disease appears not as a mucous patch but as a chancre. It is from mucous patches that infection is most to be feared in dental practice.

PRIMARY SYPHILIS OF THE MOUTH.

The primary lesion of syphilis, chancre, is found in the mouth in consequence of direct infection, carried from a syphilitic. The infection may occur from contact of the mucous surface of the mouth with a syphilitic lesion upon another person. It has been transmitted by kissing. It may occur from using a glass or cup previously used by a syphilitic, by smoking cigars or cigarettes which have been made by syphilitic cigar-makers who have applied the tongue to the tobacco in attaching the wrapper.

Any of the articles named or the contact of any article which has been in contact with a syphilitic lesion, if brought in contact with an abraded mucous surface, is very likely to cause infection. The infection may be transferred from patient to operator if the fingers have any abraded surface, or if the surface is broken accidentally by an instrument. Infection may be transmitted from one patient to another by any instrument, appliance, or article used by the syphilitic being afterwards used by an innocent person. Drinking-glasses, mouth-mirrors, exploring instruments, rubber dam, rubber-dam clamps, lancets, forceps, or any other instruments, may be the medium of communication. During and since the time of Hunter, the use of teeth from syphilitic patients in plantation operations has been a clearly recognized medium of communication.

"The primary lesion of syphilis never makes its appearance before ten days after infection; the maximum period is about ninety days, the average is twenty-one days." (Gross.)

It usually appears as a single elevated papule; in cases of dental infection frequently about the lips; the papule loses its epithelial coating after some days. The hardening surrounding the papular mass increases until the papule, which is now raw and in a process of ulceration, appears surrounded by a ring of cartilaginous hardness. This induration is the one distinguishing feature of the

chancre, which is not painful. In about a week after the appearance of the primary sore swelling of the submaxillary lymphatic glands is observed. "In case the chancre appears upon the tongue, the subhyoid lymphatic glands are swollen" (Park). Unless pyogenic infection has occurred, the lymphatic involvement is not inflammatory, there being no pain in the glands.

In from three to four weeks the sore disappears; in some cases leaving no sign of its site, in others some induration may persist.

The diagnosis of this condition is the important consideration so far as the dental practitioner is concerned, its constitutional treatment being the office of the general surgeon.

The elevation of the sore, its induration, and, if obtainable, the date of inoculation are diagnostic data. The sore is single, and there is hard, nodular, painless swelling of the neighboring lymphatics. A single ulcer of ulcerative stomatitis may in some degree simulate the appearance of chancre, for it may exhibit slight induration. Their irregular form, situation, painfulness, and usual absence of lymphatic involvement, together with their prompt disappearance after sterilizing the mouth and cauterizing of the ulcer, will differentiate the two sores.

It is a wise precaution, however, to view all sores about the mouth as possibly infective; all errors of diagnosis in this direction will be more than compensated for by the assurance of non-transferrence of infection.

SECONDARY SYPHILIS OF THE MOUTH.

The secondary manifestations of syphilis are observed in and about the mouth, no matter where the location of the primary lesion may have been; they are the result of a general, not a local, infection.

Secondary affections of the mucous tissues appear in from four to twelve weeks after the appearance of the primary lesion. Sore throat due to inflammation of the mucous membrane of the pharynx and parts about is almost constant, together with syphilitic hoarseness due to the extension of the affection to the mucous membrane of the larynx. Symmetrical and usually painless, shallow ulcers of the tonsils are characteristic. The appearance of copper-colored areas upon some portion of the mucous membrane, on the tonsil, pharynx, soft palate, lips, or bucco-labial surface, precedes the loss of epithelium over such surfaces, which soon occurs, forming the most virulently contagious lesion of syphilis, the mucous patch.

These become covered with a grayish-white pasty coating re-

sembling the ulcerations of non-specific stomatitis; so close is the resemblance that a differentiation can only be made at times by additional evidences of secondary syphilis. Single patches may coalesce, forming large, irregular areas covered by a grayish-white pellicle. These patches are rarely painful. Ulcerations having ragged, irregular outlines may appear at the sites of the original patches or in other situations which exhibit a tendency to spread. The diagnosis of the condition is determined by a discovery of other lesions of secondary syphilis, skin-eruptions, falling out of the hair (alopecia), and by the areas of copper-colored eruption upon the mucous membrane of the pharynx and soft palate. Hugenschmidt has found the frequent nocturnal occurrence of indefinitely located dental pains spreading to the palatal region in the absence of local lesions.

TERTIARY SYPHILIS OF THE MOUTH.

The syphilides of the secondary stage arise in and are confined to the mucous and submucous structures of the mouth; those of the tertiary stage arise in the deep connective tissues, and are frequently associated with periosteum.

Tertiary lesions as seen by the dentists are usually in the form of ulcers, of first the soft or hard palate of the tongue or lips. In the earlier stages hard, nodular formations may be noted as antecedents to the ulcerations. Chronic periostitis of the palatal process may occur, leading to the formation of localized thickenings. In other cases localized swellings in the soft palate may occur; the overlying mucous membrane breaks, establishing an ulcer, which may perforate the soft palate, destroy a portion of the palatal process, or form large ulcers on the tongue. These lesions appear in from two to five years after the secondary manifestations. Although there is much doubt as to the infectiveness of these tertiary lesions, precautions as to sterilization should be taken as with the primary and secondary lesions.

A defined ragged ulcer occupying the hard or soft palate, which has persisted for a long time, is always viewed with suspicion, and a search is made for other evidences of syphilis. These ulcerations appearing upon the side of the tongue may closely simulate epithelioma of that organ; the confusion is increased if in consequence of the presence of jagged teeth a continuous irritation is excited. Moreover, leukoplakia of the cheeks frequently accompanies tertiary syphilis. An absolute diagnosis is only made out in some cases

by noting the disappearance of the local lesion upon the administration of iodides, the specific treatment of tertiary syphilis.

In any of these conditions, particularly those named under the head of secondary affections, extraordinary precautions should be taken to prevent transmission of infection. Every instrument or article brought in contact with the mouth of the patient should be set aside for special sterilization. Napkins used upon such patients should be thrown away; the same applies, of course, to rubber dam and saliva tube ejectors. All other articles should be immersed in an antiseptic solution, say a five-per-cent. lysol solution, and be afterwards boiled for fifteen minutes in a two-per-cent. solution of sodium carbonate, not bicarbonate.

Forceps, rubber-dam clamps, and mouth-mirrors need special attention. Should the fingers of the operator have any abrasions upon them, it is the part of prudence not to insert them in the syphilitic mouth, certainly never without first covering the abrasions with collodion or an impenetrable varnish.

The above excerpt is as much material relative to this subject as the plan of the text-book from which it is taken admits. This might be expanded to any length, however. The principal object in presenting this matter, with the illustrations, is to point out the more usual oral manifestations of syphilis, their relative infectiousness, and their diagnosis.

The picture of the chancre represents an outlined sore upon the lower lip; similar sores may be seen upon the gums, the tongue, the pharynx, and other parts. If on the tongue, they may be very large instead of small, as here represented; the mechanical irritation of bruising against irregular teeth, or their sharp edges, may cause very angry-looking and extensive sores.

This applies also to the secondary sore which is depicted under similar conditions, and particularly in the mouths of confirmed smokers, where secondary lesions are most extensive. Under these conditions the lesions of secondary syphilis may acquire the appearance of tertiary lesions. This is of decided importance, because it is the lesions of secondary syphilis which are the highly infective ones, even more, the saliva is probably infective, whereas it is doubtful whether tertiary lesions are infective.

The gumma in the palate is represented in the submucous tissue prior to discharge and ulceration. The phagedenic nature of these tertiary sores is shown in the lesion of the lower lip where the deep muscles of the lip are invaded.

I show you also representations of Hutchinson's teeth, diagnostic signs of hereditary syphilis. You will observe that the malformation is confined to the upper central incisors; this is a general but by no means universal truth, for the malformation may involve the other teeth also; this, however, is unusual. Williams has shown that the dentine of such teeth is very badly organized, as is also the enamel; but the formative organ of the latter tissue is disordered in function and form; not only is the enamel built with great irregularity as to its elements, but the functional activity of the ameloblasts ceases too soon. The teeth formed during the eruptive fevers are shown in contrast; it will be seen in these, that while the teeth have almost their normal forms, enamel-building has been checked at an early period, affecting all of the developing tooth, but when the nutritive equilibrium is re-established enamel deposit proceeds normally.

The President.—The subject is now open for discussion, and a very interesting subject it is. I am sure that any practitioner of any number of years' standing has met in mouths, where he least expected it, the manifestation of syphilitic virus, and it behooves the dentist, above all men, to be constantly on the lookout for just this condition of things.

I am very glad that Dr. Burchard has called attention to the distinction between syphilitic teeth and atrophied or imperfectly developed teeth. They are very frequently mistaken. I frequently have patients brought to me with what are purported to be syphilitic teeth, when they are nothing more nor less than these imperfectly developed teeth, consequent upon some insufficiency in nutrition.

The paper is now open for discussion.

DISCUSSION.

Dr. E. C. Kirk.—Mr. Chairman, I wish first to express my appreciation of the very clear presentation that Dr. Burchard has made of this very interesting subject. I wish especially to commend his drawings illustrating the several lesions which he has described, and, further, incidentally to call attention to the very great desirability of having drawings of this character made by a dentist. I think they are the first drawings of this character, either anatomical or pathological, in which the human teeth have been represented as human teeth. They evidently bear the impress of a man who knows something of tooth-formation. They show that they were drawn by a dentist.

My first professional acquaintance with syphilis occurred, I think, in 1877, in listening to a lecture on this subject by the late Professor Agnew; and I was impressed at that time with the very great importance of the ability in the practitioner to recognize the characteristic features of syphilitic lesions, especially because of the necessity for protecting one's self and one's patients from the horrible results which might occur from any mistake in regard to diagnosis in this matter. Later on, when I took dental lectures, the subject was again impressed upon my mind, and I think that, as a graduate, I left college fully impressed with the great importance of recognizing these conditions. But as I went on in practice I found very few cases, and in looking back over perhaps twenty years of experience in contact with people of all sorts and conditions, the number of syphilitic lesions that I have observed in the mouth has been remarkably few. I made a sufficiently careful study of the subject to be able to recognize secondary, tertiary, and primary manifestations of this disease in the mouth; but, as I say, the cases that have come to me have been extremely few in proportion to many other disorders, much less than I had anticipated from the instruction I received at college and the feeling that I had absorbed in regard to it.

I have seen a number of cases of secondary lesions in the mouth, and they have been sufficiently described by the essayist. I think we could all remember cases of this character. The same with the tertiary lesions.

It was my good fortune at one time—and only one time in my career—to meet with a primary syphilitic lesion in the mouth; the case was of peculiar interest to me. It has never been reported, and I am glad of the opportunity to report it this evening. There was a necrotic patch or area just above the gingival margin of the upper left cuspid tooth, just as though a half-rounded chisel had cut out the gum tissue and left a base which was clay-colored, having the general characteristics of a mucous patch, but the edges were indurated. There was no pain to speak of, and no other lesion of the soft tissues of the mouth, but on examination I found a marked induration of some of the submaxillary and cervical lymphatics. The condition had existed for about ten days. Because of the peculiar appearance of the necrotic patch, because of the history of the case, because of its general clinical characteristics, and because of the induration of the lymphatic glands, I suspected that it might be a case of primary chancre. It was not complete; it was crescentic in character, not fully rounded, but looked as if infection had taken

place at the gingival margin, and because of its location of circumference could not be completed. I dismissed the case for the time being, sent for the gentleman who referred the case to me, and asked him, if possible, to endeavor to ascertain the previous history. The girl told me that she had injured this gum-tissue with a tooth-brush, and this sore followed. I learned afterwards that while she was employed as a domestic in a boarding-house she had utilized the tooth-brush of one of the boarders to perform her dental toilet, and, as he was suffering from secondary syphilitic lesions of the mouth, the virus had been conveyed in that way. It is the only case of primary syphilis of the mouth I have ever seen, and was interesting because of its history and the method of transmission.

We are instructed (as we have been in the paper this evening) as to the especial care necessary to protect not only our patients, but ourselves, from syphilitic infection in the use of instruments. I heartily agree with all that the essayist has said as to the necessity for the sterilization of instruments and the maintenance of an aseptic condition of everything that goes into the mouth; and it seems hardly necessary to emphasize that, because it is presumable that the general principles of antiseptic surgery should apply to all dental operations without regard to their specifically infectious character.

The question, however, of the contagiousness of syphilis is one that has interested me greatly. I have on two occasions, in operating for syphilitic patients where the lesions of the secondary stage existed, by accident subjected myself to the chances of infection, and have been caused a great deal of subsequent anxiety because of the possibility of personal infection. On one occasion I wounded my index-finger with a plugger-point, and thought I was certainly infected with syphilis, but by careful sterilization of the wound, and by promotion of free bleeding at the time, no ill results followed.

On another occasion, in scaling the tooth of a patient whose mouth was affected with mucous patches, a particle of tartar sprang out of the mouth, passed beneath my glasses, and struck the sclerotic. I washed out the eye with warm water, and never had any difficulty. I am not immune from this disorder, but it shows that syphilis is not as contagious as it may have been considered; and, as a matter of fact, I think Dr. John Musser (of the University of Pennsylvania) within two or three years has written an essay on this particular point, showing that there is ground for belief that

the type of syphilitic infection in later years has undergone considerable modification, that is to say, it is not as virulent as it was in its earlier history. How far that is true, I do not know.

As to the question of tertiary lesions of syphilis from a practical point of view, a case was referred to me recently of tertiary syphilis, with perforation of the hard and soft palate, not involving the distal border of the velum, but simply a large oval area of the hard and soft palate. The case was referred to me at the University, with the request that an obturator or an appliance be made to close this opening, in order that the patient might be able to masticate food and swallow better. I found that the edges of this opening were very much indurated, that the disease was still in an active state, that the inflammatory process was still active, that there was quite a considerable amount of bleeding from the margins of the opening, and from the fact that a flat obturator introduced under these circumstances would be in itself an irritant, I advised a postponement of mechanical treatment of the spot until the tissues could be brought to a more healthy condition. I felt sure of my ground at the time, but in thinking it over I have thought perhaps I might have been in error, and that the temporary closing of the orifice might have aided in the process of healing by relieving the tissues from irritation by food substances taken into the mouth. I would be very glad to have the judgment of my colleagues as to whether an obturator ought to have been inserted or postponed, as I advised, until the tissues were well.

Dr. M. H. Cryer.—I would like to thank Dr. Burchard for his paper, and to ask him a question as to whether the teeth on the lower row in the drawing were not caused by salivation before the formation of enamel. In regard to Dr. Kirk's question, as to inserting an obturator before the orifice was healed, I should certainly not recommend it. No matter how carefully constructed, it would be an irritant. The exudations from this sore would be conveyed to other portions in contact with the mucous membrane. I should much prefer deferring the placing of the obturator until the tissues were in better condition.

Dr. H. B. Roberts.—I would like to ask Dr. Burchard if it is possible for syphilis of the mouth to continue for periods running into years without destructive processes going on afterwards. I had as a patient a child that I believed to be syphilitic—born so; it is now nearly twelve years old, has never been able to talk intelligently, cannot walk without assistance, and its mouth seemed almost a mass of white mucous patches, located first at one place,

then at another. The child was under my care for three or four years; she always came in with the same condition, and yet there was never any destruction of the tissues other than the mucous patches.

The only other case that I came across was that of tertiary syphilis with an ulcer half-way through the tongue. I had not suspected syphilis. I referred him to a physician, and he afterwards came back again with his tongue in a more healthy condition, following the use of iodides.

The President.—We have with us this evening a gentleman from the medical profession in the person of Dr. Schamberg. I am sure the Society will be glad to hear from him.

Dr. J. F. Schamberg.—If I may be permitted to make a few remarks, I will preface them by thanking Dr. Burchard for his very admirable paper, and by stating that I would endorse *in toto* all the remarks he has made.

There can be no doubt whatsoever as to the importance of syphilis in relation to dental surgery. The disease is so widespread that many cases must of necessity come to the hands of the dentist, and particularly now, inasmuch as it is the custom of physicians who are treating cases of syphilis to send them, immediately upon the recognition of the disease, to a dentist for the purpose of putting the mouth into proper shape.

We are aware of the fact that caries of the teeth and stumps in the mouth predispose to oral conditions in syphilis, to mucous patches, and other forms of syphilitic infection, and therefore dentists will be very apt to have cases of this nature come under their charge.

In the early stages of syphilis the disease is greatly contagious; and I may add here that it is not only contagious when there are certain lesions in the mouth, such as the initial lesions, chancre, and mucous patches, but it is contagious through the saliva when there are no oral lesions. I believe that the view of eminent syphilographers is that the virus of the secretions of the body in the second or constitutional stage of syphilis is infective, the tears, the saliva, very often the secretions of the stomach, and others. Therefore, even though there be no lesions whatsoever in the mouth, there is a possibility of infection, and the very practical point that this brings up is the thorough sterilization of all dental instruments after treatment not only of suspicious mouths, but of all mouths, because no one knows whether it is a syphilitic mouth he is treating or not. There are many cases of syphilis to-day going about

without any cutaneous manifestations whatever, without any systemic or oral manifestations, and yet they are just as capable of transmitting this disease as if they were covered with these lesions.

Syphilis is a protean disease, manifesting itself in various ways, and Dr. Burchard has well illustrated the chief types of this disease, as well as its relation to the mouth.

I can state, in relation to Hutchinson's teeth, that Mr. Hutchinson says that the characteristic Hutchinsonian teeth are the upper central incisors. When other teeth are infected, they may be syphilitic teeth, but they are not pathognomonic; and the features are that crescentic excavation upon the free border of the tooth, the discoloration of the tooth, and, shortly, what he calls the "pegged-shape" tooth. The free border is of much less breadth than the gingival or alveolar border.

As regards the secondary patches of the mouth, they are very commonly confounded with lesions of this cavity. A great many skin affections, such as herpes and other disorders, always have concomitant lesions in the mouth, and herpes soon breaks down, the covering rupturing and exposing to view a small reddish abrasion, which may be readily mistaken for a mucous patch. However, this matter of diagnosis is not of vital interest to the dentist, inasmuch as the question is, Shall he sterilize or exert any particular care or not?

In the tertiary lesions of syphilis of the mouth we have the gummata and what results therefrom,—the deep ulcers; and it may be stated in general that the tertiary lesions of syphilis differ from the secondary in their deeper destruction; they destroy more and go more deeply, involving not only the submucous tissue, but also the bone and cartilage. In connection with these ulcers, one may lead to other ulcers in the mouth. There are epithelioma and tubercular ulcers, and I will say that it is extremely hard to differentiate them.

Syphilis is an extremely important disease, and I should like to correct any impression that may exist as to its infrequency. It is a very frequent disease, and, it may be stated advisedly, that it is just as frequent in high social stations as it is in low, not only abroad, but in this country, and almost every day dentists are bound to have patients come into their offices who have or have had syphilis.

An oral difference which may come under notice of the dentist is the peculiar whitish discoloration of the tongue or buccal mucous membrane; it is termed leucoplakia buccalis, or mucous

plaques, and other varieties; some have been termed para-syphilitic. They are not due directly to syphilis, but to the ulterior influences of this disease. They are in many cases due to an irritation of the stomach, and this is perhaps the most frequent form. There is a form of syphilis which people have had in which a precedent syphilis has had some etiological influence.

I thank the Society for the courtesy extended to me in permitting me to make these remarks.

Dr. J. H. Gaskill.—I would like to ask Dr. Burchard a question. I had a case of syphilitic origin which involved the pharyngeal muscles, the soft and hard palate, the nasal bones, and a portion of the maxillary bones. The bones of the nose and a portion of the maxillary bone had to be removed, allowing the soft tissues of the nose to fall in, and making the face very flat. This allowed the end of the nose to point upward, elongating the nostrils and giving the patient so bad a deformity of the face that I have made him a false nose. I would like to ask whether there is a possibility of the irritation from the attachment of that nose inducing a trouble of another kind. To get a firm hold for that artificial substitute, I have made hard-rubber prolongations into the nostrils, and also passed a hook back of the lip; the upper part is held in place by spectacle frames.

Dr. H. H. Burchard.—The answers to Dr. Kirk's and Dr. Gaskill's remarks both come under one head. The conditions they describe belong to the lesions of tertiary syphilis. Where these tertiary lesions of syphilis are present they are regarded as a local disease. They have this peculiarity, that they are locally infective, have a disposition to travel, and run a phagedenic course, and it is with extreme difficulty that they can be checked. So that in relation to Dr. Kirk's case, where the lesions are only partially healed, I deem it advisable to defer prosthesis until the healing is completed, after a course of iodide.

In Dr. Gaskill's case, the degree of pressure permissible depends largely upon the thoroughness of the eradication of syphilis. There is always danger of precipitating degenerations in syphilitic tissues, so that I should say, be guarded in the amount of pressure and its kind for a long period. Certainly, if the patient had any evidence of syphilis remaining, there would be danger of deep breaking down of the tissue caused by this kind of irritation.

In regard to Dr. Cryer's question as to whether the Hutchinson teeth, or the other types of teeth shown here, could be caused by mercury or not, the best evidence in this matter is that of Hutch-

inson himself. It is a curious thing that, while during this time the upper central and all of the incisors are in process of formation, these two teeth, as a rule, should be the only ones affected. In mercurial cases all these teeth are affected,—for example, when half the crowns of the upper central incisors are affected, about one-third the crowns of the lateral incisors and the tips of the cuspids are affected, and a large portion of the lower incisors. But in syphilis the pathognomonic teeth are the upper central incisors; the lower incisors may be perfectly normal. That is usually regarded as the point of differentiation between the two. In syphilitic children who have had a course of mercury, the teeth often show evidence of faulty enamel formation; they have deep transverse grooves running across the crown, but these teeth show no evidence of gross malformation.

Dr. Roberts's question I would refer to Dr. Schamberg. In hereditary syphilis, as in this case, the lesions about the mouth would not have come under the head of mucous patches; these latter are fungating ulcers which disappear with the other manifestations of secondary syphilis. It has been maintained that syphilis is a self-limited disease in the sense of having a definite course. If no mercury were administered during the primary or secondary stage, and if no iodides were administered prior to or during the tertiary stage, then syphilis would run a distinctive course, the mucous patches belonging to the secondary constitutional stage. But as to the question why these ulcers in Dr. Roberts's case persisted, Dr. Schamberg will furnish him the answer.

Dr. J. F. Schamberg.—I should state that at times, in syphilitic individuals, even the administration of the iodides of mercury would not be sufficient to dissipate any lesions of that disease, provided there was marked malnutrition. At times the so-called therapeutic test is not worked. And if these ulcers be syphilitic and do not heal, and the patient be under large doses of iodides and mercurials, then he may be classed as belonging to this group, in which the general condition of the patient was such as to fail to give the treatment a proper hold and fail to stimulate the regeneration of the tissues.

INCIDENTS OF PRACTICE.

Dr. Otto E. Inglis.—Under this heading I may report a case which has come to a happy conclusion, in the Philadelphia College clinic, of a young boy about twelve years of age, who tripped in crossing a room and fell against the arm of a chair. In that fall

he knocked out three of the inferior incisor teeth, which remained out two days before he came to the college. Those teeth were prepared and sterilized according to instructions generally given for replantation; the sockets were enlarged, and the teeth replanted and ligated with a simple ligature of silk. This was done five weeks ago, and at the present time the teeth are quite firm. I do not propose to take off the ligature for two weeks, though they are quite firm without it, as I have tested them.

Dr. H. C. Register.—I had an interesting case that commenced over two years ago,—a lady, who, after being under the care of a physician for perhaps two or three weeks, suffered very intensely with neuralgic pains through the base or occipital portion of the cranium and through her eyes. Getting no relief, she concluded that she would have me examine her teeth. On careful examination, I found the first bicuspid gave some response to a very hot blast of air, but could get no response from any of the other teeth by tapping, by cold water, or by any of the tests I used, with the exception of the blast of hot air. That gave me the impression that there was something unusual the matter with the first bicuspid. I concluded to go into the pulp, and I found that it was affected with calcification. It was the only positive condition of granular calcification of the pulp that I have ever had in my practice. In breaking up the remainder of the pulp, it was extremely painful, but ultimately I did succeed in doing it, to her entire relief. The pain in her head discontinued, and she was a well woman, and continued so until about two months ago, when she said the same pain was reappearing, more markedly in her eyes than anywhere else. I found by tapping the second bicuspid that a little soreness was present, and upon entering it I found complete calcification of the pulp. I cut until I was afraid I would go into the cementum and alveolus. I did reach nearly the apex, and there I found an infinitesimal portion of pulp matter which was exquisitely sensitive, so that it was with great effort that I succeeded in destroying it. I asked if her eyes had been examined, and she said, "No;" so, remembering what Dr. Garretson had said to us about cataracts, I made a pinhole through a card, and asked her to look through it. She found she could not see a round hole; she saw an oblong hole. I conferred with her husband, and said I thought cataracts were probably forming. She was taken to an oculist, who pronounced that such was the case.

The question is, Is the formation of cataracts of the eye coincident with calcification of the pulp of the tooth, or is there some

power at work in the system that has produced one and is producing the other?

Dr. H. H. Burchard.—This is a deeply interesting subject that Dr. Register has just brought up, and if it were not, I would not take up any more time in the discussions. There is a constancy in the reactions occurring from the conditions Dr. Register has described; these pathological conditions of dental pulp belong under the head of deeper degenerations of the pulp, and this reaction is quite characteristic of these conditions; wide-spread reflex neuralgias are also characteristic. Setting aside any differentiation of the several types of deep degenerations, and taking up the question of reflex troubles in the eye alone, they are of extreme interest and importance both to the dentist and general practitioner. There was one case where amblyopia followed upon degenerative changes in the dental pulp. This amblyopia persisted for about twelve years, when a septic pericementitis occurred about the tooth. As soon as this was remedied, the eye condition materially improved, and it grew decidedly worse upon the reappearance of septic infection about the root of the same tooth, and then became better after the tooth was extracted; that is, blindness returned when the vent for the pus was blocked up, and partially disappeared upon extraction of the tooth.

In regard to the types of these degenerations, we must differentiate between them. The first stage is where there is an exaltation of the formative function of the odontoblasts, resulting in the formation of secondary dentine. In such cases there is no painful reaction, reflex neuralgias do not occur, and no abnormal response. Under the head of secondary dentine, pulp nodules are not to be placed, because it is very rarely that these structures represent the typical dentinal structures. They are formed in the substance of the pulp, and indicate degeneration. It is in these deep degenerations that wide reflex neuralgias are marked.

Hyperæmia of all the pulps of the teeth is very common in conditions of gout, and so is general hyperæmia of the pericementum.

Dr. H. C. Register.—I think this patient is gouty, though I do not know whether she has pyorrhœa.

Dr. H. H. Burchard.—A pulp-stone growing in an abraded tooth may be the cause of vicious neuralgia. If another tooth in another portion of the mouth be extracted, there may be no evidence of caries or abrasion; but on breaking up the tooth, pulp nodules may be found in greater number than in the primarily affected tooth. There seems to be a dyscrasia in that condition. Dr. Cryer handed

me a tooth where the pulp had undergone calcareous degeneration, and said this pulp gave such and such symptoms. I said the pulp is nearly obliterated by secondary growth, and that is the condition we found. There is a calcareous degeneration, and there is a deposition of calcareous matter in the pulp, but in these calcareous deposits there is more or less of anatomical form. It is a secretion, not a mere precipitation of calcium salts.

Dr. H. C. Register.—In regard to the calcareous deposits of pulp, there was a very beautiful specimen that presented itself in a patient. I had capped the pulp of a cuspid tooth, and the crown was becoming so discolored that I thought it must be devitalized, and concluded to enter the pulp. But after removing the filling I found that I was cutting secondary dentine, and to such a depth that I concluded that the pulp had become calcified. After passing through quite a stratum, I suddenly plunged into a living pulp. I suppose there must have been quite a number of lines in width of this secondary formation drilled through.

Dr. H. H. Burchard.—You may find secondary dentine deposition on the periphery of the pulp-chamber, and you may find in another portion of the pulp a nodule, evidently formed by secretion, not by precipitation, and in another portion of the pulp the precipitation of calcareous matter as a secondary degeneration.

Dr. R. Huey.—I had a personal case which was exceedingly interesting to me, inasmuch as it gave me a good deal of suffering and puzzled me. Dr. Cryer will probably be interested in it. I am a sufferer from pyorrhœa, and during the last two weeks I have suffered a great deal with a second bicuspid tooth. Any change of temperature produced excruciating pain. This is the way the tooth looked (illustrating on black-board). The cap was removed, but relief was but slight. The pulp began to die; the symptoms of death of the pulp became evident, so I concluded to have the tooth removed, remove all the pulp, and replant it. I believe one of these days we will find that to be a cure for pyorrhœa alveolaris. I proceeded to remove the pulp through the filling, and in passing into the pulp I noticed a little exudation of discolored lymph about half-way between the neck of the tooth and the apex of the root. I had before diagnosed the deposit of calculus all the way to the apex of the root, but the tooth was firmly attached. The calculus had reached the point where a slight opening occurred at about the middle third of the root, and I wondered if that had been causing the trouble, for I could have gotten up a nice little alveolar abscess.

The President.—You are sure there had been no absorption of the root?

Dr. R. Huey.—There appeared to be perfectly normal foramen to the inside of the tooth, through which there seemed to be circulation; and I am satisfied that no pressure upon the pulp took place at that point. I have the tooth; it is not yet replanted.

The President.—Absorption has taught us that the foramina through which the blood-vessels enter to nourish the tooth are not always at the apex. I apprehend, if we knew the whole truth, we would find that they are frequently not at the apex.

Dr. M. H. Cryer.—At the same time I would state that they do enter the apex.

The President.—Sometimes, but not always. When we try to put a broach through the apex, the broach may go outside, somewhere else.

Dr. M. H. Cryer.—I see how that could occur in this way: the provisional foramen was at the apex (and much cementum has been built on), and the canal deflected, but originally it was at the apex.

The President.—Yes, I have seen that in cases of hypercementosis.

Dr. I. N. Broomell.—That brings up a subject that has been interesting me somewhat of late. In investigations which I have made, I have traced the growth of the tooth from the first deposit of lime salts up to the formation of the crown. In all these specimens we have surrounding the forming crown the saccular wall. The root has extended in this manner (illustrating) because the saccular wall has extended with it. At this stage we do not have the inferior dental nerve (if you choose to use that term, for example) running up to supply the crown of the tooth. We do not have it when the root is somewhat further formed. The supply is given to a growing tooth from the surrounding (follicular) wall. It has always been a puzzle to me to know at what time this nerve and blood-vessel enter that foramen when the crown is formed.

Dr. E. C. Kirk.—What occupies the central cavity?

Dr. I. N. Broomell.—The central cavity is occupied by dentinal pulp.

Dr. H. H. Burchard.—The artery and nerves are quite distinct after the fifth month. Take a tooth at the fifth month, and you will find blood-vessels entering the pulp. If you take the follicular wall, you will find blood-vessels entering it, and between these two there is a decided space; but the vessels at the base of the pulp and entering it are marked unmistakably.

Dr. I. N. Broomell.—I am very glad that Dr. Burchard has tried to make the matter plain, but he has not made it plain to me. I have not only tried with the naked eye, but I have tried with a microscope, to find where this blood- and nerve-supply comes off. I know there is a supply of blood-vessels given off.

Dr. H. H. Burchard.—You might not have happened to hit a longitudinal axis of those blood-vessels in that pulp.

Dr. I. N. Broomell.—But after the tooth is fully developed, we have a nerve and blood-vessel entering the foramen.

Dr. H. H. Burchard.—The blood-vessels come in like this (illustrating); Dr. Cryer has shown it. In the early stages of the formation of the jaw the inferior dental artery is of a certain length. As the jaw develops it becomes longer, and at this portion it is ramified (illustrating), until it breaks up into an Haversian system, sending vessels into the pericementum, and these communicate over the external alveolar wall with those of the maxillary periosteum; but in some cases I have no doubt that a vessel may give off branches and run right into the apical space.

Dr. E. C. Kirk.—The nutritive supply is unquestionably in the general papilla which forms the pulp; that should settle the question.

Dr. M. H. Cryer.—Dr. Burchard said I have shown the canals which transmit vessels and nerves to the apical space. I can show the nerve in position in these canals.

The President.—In the inferior dental canal?

Dr. M. H. Cryer.—Yes, and beyond it.

The President.—They are very distinct in the lower animals,—the calf, for instance.

Dr. H. H. Burchard.—The reason the vessels acquire their distinctness at later stages is because the dentine grows in about them and obliterates nearly all the vessels. Where there may be a dozen arteries in the dental pulp at six months, at the time of eruption there may be only two or three. I can demonstrate in sections arteries and nerves lying beneath the formative pulp.

Adjourned.

OTTO E. INGLIS,
Editor Academy of Stomatology.

OFFICERS.

1898-99.

PRESIDENT.

E. T. DARBY.

VICE-PRESIDENT.

M. H. CRYER.

SECRETARY.

I. N. BROOMELL.

TREASURER.

H. L. ROBERTS.

LIBRARIAN.

W. H. TRUEMAN.

INDEX.

Agnew, Professor D. Hayes, reference to, 66.
Amalgam in bridge-work, 39, 40.
copper, 32, 44.
Amblyopia from dental cause, 74.
Amendment to constitution, 28.
Ampèrage in cataphoresis, 9.
Amputation of root, 45.
Andrews, Dr. R. R., reference to, 40.
Arsenic, antidotes for, 54, 56, 57, 59.
coverings for, 54, 58.
experiments with, 46.
necrosis from, 46, 55.

Bennett, Dr. H. D., reference to, 37.
Bibliography, Dental (essay), 23.
Bing, Dr. B. J., reference to, 37.
Black, Dr. G. V., reference to, 18.
Bleaching, clinic on, 15.
Bridge-work, amalgam and cement in, 38, 39, 40.
Mason crown in, 40.
priority in, 37.
plastic operation on gum in, 41.
self-cleansing spaces in, 38.
Some Features (essay), 37.
split shells in, 40.
Broomell, Dr. I. N., remarks by, 76, 77.
Burchard, Dr. H. H., remarks by, 1, 60, 71, 74, 75, 76, 77.

Capon, Dr. W. A., report of clinic, 13.
Caries, John Fuller on (reference), 25.
Dr. W. D. Miller on (reference), 25.
recurrence of, 12.
Dr. J. L. Williams on (reference), 25.
Cataphoresis, apparatus for, 9.
application of current in, 9.
clinic on, 15.
Cataract, diagnosis of, 73.
Cavities, sterilization of, 12.
Cells, silver chloride, 9.
Chance, Dr. G. C., remarks by, 57.
Clinics held, 1, 11, 13, 15, 28.
Constitution, amendment to, 28.
Cooke, Edmund Garretson, gift in name of, 1.
Copper amalgam, antiseptic properties of, 32.
discoloration by, 44.
Crowns, 13, 40.
Land jacket, 13.
on perforated roots, 34.
Cryer, Dr. M. H., remarks by, 1, 7, 68, 76, 77.

Darby, Dr. E. T., remarks by, 22, 44, 76, 77.
Delabarre, C. J., reference to, 37.
Dentin, relation to fillings, 11.
reformation of, after pulp-capping, 8.
senile, 23.
Dialyzed iron as antidote to arsenic, 56, 57, 59.
Dies, jewellers', threads of, 19.
Discoloration by copper amalgam, 44.
Discussions, society, 6, 22, 30, 43, 56, 65.
Druggists, carelessness of, 57.

Enamel, preparation of, for filling, 11.
Erosion as sign of gout, 16, 22.
Eustachius, reference to, 25.
Evans, Dr. George, reference to, 31.

Ferric hydrate as antidote to arsenic, 54, 56.
Fillings, relation of, to enamel and dentin, 11.
Fitch, Dr. S. S., reference to, 37.
Foramina, enlarged, treatment of, 44.
Fuller, John, on dental caries, 25.
reference to, 25.

Gardiner, Dr. F., remarks by, 23.
Garretson, Professor James E., symposium upon, 1.
vote of thanks to family of, 1.
Garriot, Dr. J. B., reference to, 37.

Gaskill, Dr. J. H., remarks by, 71.
Germs, dental, Eustachius on, 25.
Gilliams, Dr. J. S., essay by, 15.
Girdwood, Dr. John, essay by, 31.
Gold, adaptation of, 11.
    anchorages for, 13.
    packing, by bibulous paper, 12.
Gout, acute therapeutics of, 18.
    dental manifestations of, 15, 22.
    hyperæmia of pulp and pericementum in, 74.
Gross, Dr. Samuel, reference to, 61.
Guilford, Dr. S. H., remarks by, 6, 30, 45, 56.
Gums, arsenical necrosis of, 46.
    plastic operation upon, 41.
    recession of, 22.

Hernia, pericemental, 31.
Herpes, 70.
Hickman, Dr. H. B., remarks by, 57.
History, dental, Dr. William H. Trueman on, 23.
Huey, Dr. R., remarks by, 75, 76.
Hunter, Dr. John, reference to, 61.
Hutchinsonian teeth, 65, 70, 71.

Incidents of practice, 8, 72.
Infection, mode of, in syphilis, 61, 64, 67.
    personal, 67.
Inglis, Dr. O. E., remarks by, 43, 46, 58, 72.
Iodides in syphilis, 64, 72.

Jack, Dr. Louis, remarks by, 8, 9, 10, 22, 28, 30.
Jam-plate, use in orthodontia, 19.

Kirk, Dr. E. C., lantern exhibit by, 23, 24.
    remarks by, 65, 76.

Land jacket, 13.
Lecluse, M., reference to, 25.
Leucoplakia in tertiary syphilis, 63, 70.
Library, gifts to, 1.

Mason crown, 40.
Matrices, use of, 12.
McQuillen, Dr. J. H., reference to, 46.
Meetings regularly held, 1, 11, 28, 46, 60.
Microscopes, early, 24.
Miller, Dr. W. D., references to, 25, 30.
Mouths, flat, cause of, 16.
Musser, Dr. John, reference to, 67.

Nasmyth, Alexander, references to, 23, 24.
Necrosis, arsenical, 46.
Neuralgia from calcific degenerations, 73, 74.
Nose, artificial support to, 71.

Odontology, Elements of, volume by Lecluse, 25.
Oral surgery, Garretson's influence on, 2.

Park, Dr. Roswell, reference to, 62.
Perforation of root, 31.
    amputation for, 45.
    causes of, 31.
    crowning after, 34.
    Dr. John Girdwood on, 31.
    methods of treatment, 31, 32, 43, 45.
Pericementitis, calcic, 22.
    phagedenic, 18, 28.
Pericementum, hernia of, 31.
Phosphate of zinc in bridge-work, 38, 40.
Pins, waxed, for removal from root, 35.
Plantation of teeth, 28, 72.
    method of, 29.
    nature of bony union in, 30.
Plastic operation on gum-tissue, 41.
Porcelain jacket, Land's, 13.
Prosthesis, nasal, 71.
Pulp, capping of, 8.
    degenerations of, 8, 73, 74.
    nodulation of, 9, 74.
    reflex neuroses from, 73.
Pyorrhœa alveolaris, 16, 17, 22, 75.
Pyrozone for bleaching, 15.

Reflex neuroses, 73, 74.
Register, Dr. H. C., remarks by, 11, 22, 23, 37, 44, 56, 73, 74, 75.
Regulation of teeth, 18.
    annoyances in, 19, 23.
    appliances in, 19.
    forces used in, 21.
    remuneration for, 22.
    retention after, 23.
    Dr. H. E. Roberts on, 18.
    time required for, 21.
Replantation of teeth, 28, 72.
Retention, appliance for, 29.
Rhein, Dr. M. L., reference to, 37, 38, 40.
Rheumatism, dental manifestations of, 16, 17, 22.
Riegal, E., reference to, 57.

Roberts, Dr. H. E., remarks by, 1, 10, 15, 18, 22, 30, 45, 68.
Root, perforation of, 31.
amputation of, 45.

Schamberg, Dr. M. J., remarks by, 58.
Dr. J. F., remarks by, 69, 72.
Serres, reference to, 24.
Split shells in bridge-work, 40.
Sterilization, 12, 64, 69, 70.
Stomatology, Garretson's influence on, 2.
Syphilis, Dr. H. H. Burchard on, 60.
contagiousness of, 67, 69.
diagnosis of, 60, 66, 70.
hereditary, 68.
infection in, 61, 64, 67.
iodides in, 64, 72.
manifestations absent, 69.
of mouth, 60, 69.
period of incubation of, 61.
primary, 61, 66.
protean character of, 70.
secondary, 62, 66, 70.
stages of, 60.
tertiary, 63, 68, 70, 71.
obturators in, 68, 71.

Teeth, exfoliation of, 23.
Hutchinsonian, 65, 70, 71.
regulation of, 18.
replantation of, 28, 72.
voluntary movement of, 28.
Thomas, Dr. J. D., remarks by, 28.
Tissues, destructive degeneracy of, 23.
soft, condition of, in pyorrhœa, 16.
Tooth-formation, 76.
origin of blood supply, 76.
Trueman, Dr. W. H., remarks by, 23.
Truman, Dr. James, remarks by, 7, 22, 30, 44, 56.
Tubules, obliteration of, 23.

Ulcers of the mouth, 70.

Voltage, 9.

Webb, Dr. M. H., reference to, 37, 38.
Wells, Dr. Horace, memorial bust of, 28.
Williams, Dr. J. L., reference to, 12, 23, 24, 30, 65.
on dental caries, 25.

Igal.
203

DUDOLZER
BINDER
POSTON MASS